

Oculoplastic Surgery Atlas

Springer

New York

Berlin

Heidelberg

Hong Kong

London

Milan

Paris

Tokyo

With Illustrations by *Timothy C. Hengst, CMI*
With Contributions by

Robert Alan Goldberg MD

Professor of Ophthalmology
David Geffen School of Medicine at UCLA
Chief, Orbital and Ophthalmic Plastic Surgery
Jules Stein Eye Institute
Los Angeles, California

Bradley N. Lemke, MD, FACS

Clinical Professor
Department of Ophthalmology and Visual Sciences
University of Wisconsin School of Medicine
Madison, Wisconsin

Mark J. Lucarelli, MD

Associate Professor
Director, Oculoplastics Service
Department of Ophthalmology and Visual Sciences
University of Wisconsin-Madison
Madison, Wisconsin

John G. Rose Jr., MD

Oculofacial Surgery
Davis Duehr Dean Oculoplastics Service
Department of Ophthalmology and Visual Sciences
University of Wisconsin
Madison, Wisconsin

César A. Sierra, MD

Assistant Clinical Professor
Department of Ophthalmology
Yale University School of Medicine
Attending Physician
Department of Surgery
Ophthalmology Section, Ophthalmic Facial Plastic Surgery
Bridgeport Hospital, Bridgeport, CT



Springer

Oculoplastic Surgery Atlas

Cosmetic Facial Surgery

With 38 Illustrations



Includes a DVD-ROM

DVD-ROM

Geoffrey J. Gladstone, MD, FAACS

Clinical Professor of Ophthalmology, Michigan State University School of Medicine, East Lansing, MI; Assistant Clinical Professor of Ophthalmology and Otolaryngology, Wayne State University School of Medicine, Detroit, MI; Co-Director, Oculoplastic Surgery, Department of Ophthalmology, William Beaumont Hospital, Royal Oak, MI; Consultants in Ophthalmic and Facial Plastic Surgery, Southfield, MI, USA

Shoib Myint, DO, FAACS

Assistant Clinical Professor of Ophthalmology and Otolaryngology, Wayne State University, Detroit, MI; Co-Director, Oculoplastic Surgery, Department of Ophthalmology, William Beaumont Hospital, Royal Oak, MI; Consultants in Ophthalmic and Facial Plastic Surgery, Southfield, MI, USA

Evan H. Black, MD, FAACS

Assistant Professor of Ophthalmology; Director, Ophthalmic Plastic Surgery and Orbital Disease, Kresge Eye Institute, Wayne State University School of Medicine, Detroit, MI; Consultants in Ophthalmic and Facial Plastic Surgery, Southfield, MI, USA

Brian G. Brazzo, MD, FAACS

Assistant Clinical Professor of Ophthalmology, Weill Medical College of Cornell University, New York, NY; Director, Oculoplastic Service, Department of Ophthalmology, Maimonides Medical Center, Brooklyn, NY; Assistant Attending Surgeon, Department of Ophthalmology, New York Eye and Ear Infirmary, and Manhattan Eye, Ear & Throat Hospital, New York, NY, USA

EDITOR EMERITUS

Frank A. Nesi, MD, FAACS

Clinical Professor of Ophthalmology, Michigan State University School of Medicine, East Lansing, MI; Associate Clinical Professor of Ophthalmology and Otolaryngology; Co-Director, Oculoplastic Surgery, Kresge Eye Institute, Wayne State University School of Medicine, Detroit, MI; Director, Oculoplastic Surgery, Department of Ophthalmology, William Beaumont Hospital, Royal Oak, MI; Consultants in Ophthalmic and Facial Plastic Surgery, Southfield, MI, USA

Geoffrey J. Gladstone, MD, FAACS

Clinical Professor of Ophthalmology, Michigan State University School of Medicine, East Lansing, MI; Assistant Clinical Professor of Ophthalmology and Otolaryngology, Wayne State University School of Medicine, Detroit, MI; Co-Director, Oculoplastic Surgery, Department of Ophthalmology, William Beaumont Hospital, Royal Oak, MI; Consultants in Ophthalmic and Facial Plastic Surgery, Southfield, MI, USA

Shoib Myint, DO, FAACS

Assistant Clinical Professor of Ophthalmology and Otolaryngology, Wayne State University, Detroit, MI; Co-Director, Oculoplastic Surgery, Department of Ophthalmology, William Beaumont Hospital, Royal Oak, MI; Consultants in Ophthalmic and Facial Plastic Surgery, Southfield, MI, USA

Evan H. Black, MD, FAACS

Assistant Professor of Ophthalmology; Director, Ophthalmic Plastic Surgery and Orbital Disease, Kresge Eye Institute, Wayne State University School of Medicine, Detroit, MI; Consultants in Ophthalmic and Facial Plastic Surgery, Southfield, MI, USA

Brian G. Brazzo, MD, FAACS

Assistant Clinical Professor of Ophthalmology, Weill Medical College of Cornell University, New York, NY; Director, Oculoplastic Service, Department of Ophthalmology, Maimonides Medical Center, Brooklyn, NY; Assistant Attending Surgeon, Department of Ophthalmology, New York Eye and Ear Infirmary, and Manhattan Eye, Ear & Throat Hospital, New York, NY, USA

EDITOR EMERITUS**Frank A. Nesi, MD, FAACS**

Clinical Professor of Ophthalmology, Michigan State University School of Medicine, East Lansing, MI; Associate Clinical Professor of Ophthalmology and Otolaryngology; Co-Director, Oculoplastic Surgery, Kresge Eye Institute, Wayne State University School of Medicine, Detroit, MI; Director, Oculoplastic Surgery, Department of Ophthalmology, William Beaumont Hospital, Royal Oak, MI; Consultants in Ophthalmic and Facial Plastic Surgery, Southfield, MI, USA

Cover illustration: Tim Hengst, CMI

Library of Congress Cataloging-in-Publication Data

Oculoplastic surgery atlas : cosmetic facial surgery / Geoffrey J. Gladstone . . . [et al.].

p. ; cm.

Includes bibliographical references and index.

ISBN 0-387-20079-7 (alk. paper)

1. Blepharoplasty—Atlases. 2. Surgery, Plastic—Atlases. 3. Eyelids—Surgery—Atlases.
4. Face—Surgery—Atlases. I. Gladstone, Geoffrey J.

[DNLM: 1. Ophthalmologic Surgical Procedures—Atlases. 2. Reconstructive Surgical

Procedures—Atlases. WW 17 O2125 2003]

RD119.5.E94O283 2003

617.5'2059—dc22

2003060401

ISBN 0-387-20079-7

Printed on acid-free paper.

© 2005 Springer-Verlag New York, Inc.

All rights reserved. This work may not be translated or copied in whole or in part without the written permission of the publisher (Springer-Verlag New York, Inc., 175 Fifth Avenue, New York, NY 10010, USA), except for brief excerpts in connection with reviews or scholarly analysis. Use in connection with any form of information storage and retrieval, electronic adaptation, computer software, or by similar or dissimilar methodology now known or hereafter developed is forbidden.

The use in this publication of trade names, trademarks, service marks and similar terms, even if they are not identified as such, is not to be taken as an expression of opinion as to whether or not they are subject to proprietary rights.

While the advice and information in this book are believed to be true and accurate at the date of going to press, neither the authors nor the editors nor the publisher can accept any legal responsibility for any errors or omissions that may be made. The publisher makes no warranty, express or implied, with respect to the material contained herein.

Printed in the United States of America. (MP/MVY)

9 8 7 6 5 4 3 2 1 SPIN 1093789-1

Springer-Verlag is a part of *SpringerScience+Business Media*

springeronline.com

There is no greater joy in medicine than to pass on knowledge. The benefits are innumerable. Patients receive better care; the physician practices a higher quality of medicine, and the field of medicine achieves a more advanced state by the synthesis of knowledge from many sources.

The teacher's benefits are less obvious, but just as meaningful and rewarding. Seeing residents or practicing physicians broaden their knowledge or perfecting a new surgical technique provides a wonderful sense of accomplishment. It is also a way to repay those who have selflessly given their knowledge in the past.

This book is dedicated to those who seek knowledge. It is hoped that in some small way this DVD and book will improve your practice of medicine and simplify the application of appropriate oculofacial surgical procedures.

Geoffrey Gladstone, MD, FAACS

PREFACE

The desire to teach and the fulfillment attained from teaching have again prompted us to produce a work that we hope is both useful and enlightening to our readers. The field of oculoplastic surgery has grown and evolved to include all aspects of eyelid and facial plastic surgery. Our literature must now reflect the advancements and direction of our field. Knowledge of anatomy, the basis of all surgery and the root of surgical principles and techniques, supports our ability to deliver the highest quality care to our patients.

We have therefore combined text and diagrams and supplemented them with DVD digital video technology to enable those who wish to perform this surgery the best possible instruction and preparation. We hope that our attempts to accomplish this will be rewarded by the use of this material by colleagues and the acknowledgment of our unique and logical progression in the field of eyelid and facial plastic surgery. The previous volume in this series covered reconstructive eyelid surgery. This volume presents many aspects of facial cosmetic surgery, including blepharoplasty, endoscopic forehead surgery, rhytidectomy, and other related procedures. Future volumes will present facets of lacrimal and orbital surgery.

Frank A. Nesi, MD

ACKNOWLEDGMENTS

Bringing a book project to fruition is always a complicated process involving many people. It is through their dedication, professionalism, and team effort that it all comes together.

Tim Hengst, our medical illustrator, deserves special recognition for the quality of his work and for the ease with which we communicated digitally during the illustration process. His illustrations clarify the text in a way that only visual images can.

Paula Callaghan, our editor, and the rest of the people at Springer-Verlag have been kind, patient, and helpful. Their suggestions and directions have been instrumental in producing a unique and gratifying final product.

Our fellow, Dr. Chet Reistad, acquired an unexpected skill at the beginning of his training. He has become the best videographer we have in addition to his more medically related skills. The quality of the videos starts with his excellent photographic work. Drs. Rose, Jr., Lucarelli, Cook, and Lemke contributed a concise but comprehensive overview of clinically relevant eyelid anatomy. As always, anatomy is the basis for understanding the etiology of surgical problems and provides the guideposts for surgical corrections. The high caliber of their work gives the reader an essential starting point for understanding and utilizing the techniques presented in this book.

Dr. Robert Goldberg provided an excellent chapter on endoscopic mid-face surgery. This is one of many areas where he continues to be at the forefront of cosmetic surgery.

Dr. César Sierra has contributed two informative chapters. His excellent writing about direct brow elevation and soft tissue augmentation presents techniques and pearls useful to all surgeons performing cosmetic facial surgery.

Geoffrey Gladstone, MD, FAACS

CONTENTS

Preface	vii
Acknowledgments	ix
1 Cosmetic Facial Anatomy	1
<i>John G. Rose Jr., MD, Mark J. Lucarelli, MD,</i>	
<i>and Bradley N. Lemke, MD</i>	
Forehead and Eyebrow	1
Eyelids	3
Mid-Face and Lower Face	13
References	19
2 Endoscopic Foreheadplasty	25
Etiology	25
Clinical Evaluation	26
Medical Management	27
Surgical Management	27
Fixation	33
Postoperative Care	35
3 Direct Eyebrow Lift	37
<i>César A. Sierra, MD</i>	
Etiology	38
Preoperative Evaluation and	
Incision Markings	38

	Surgical Management	39
	Postoperative Care	42
4	Rhytidectomy Surgery	43
	Clinical Evaluation	43
	Surgical Management	46
	Postoperative Care	54
5	Mid-face Lift	55
	<i>Robert Alan Goldberg, MD</i>	
	Volume Augmentation	55
	Vertical Repositioning	55
	Surgical Techniques	57
	References	62
6	Upper Blepharoplasty	63
	Evaluation	63
	Surgical Technique	64
	Postoperative Care	70
7	Lower Blepharoplasty	71
	Evaluation	71
	Surgical Techniques	72
8	Laser Skin Resurfacing	79
	Evaluation	80
	Technique	82
	Periorbital Resurfacing	82
	Perioral Resurfacing	83
	Postoperative Care	84
9	Facial Cosmetic Botox	85
	Clinical Evaluation	86
	Dilution	86

	Contraindications	87
	Procedure	87
	Complications	90
10	Lip Augmentation	91
	Etiology	91
	Clinical Evaluation	92
	Medical Management	92
	Surgical Management	93
11	Soft Tissue Augmentation	95
	<i>César A. Sierra, MD</i>	
	Collagen	96
	Hyaluronic Acid	99
	Techniques in Soft Tissue Enhancement	100
	Postoperative Treatment	101
	Index	103

ISBN 0-387-20079-7

EAN



9 780387 200798 >

COSMETIC FACIAL ANATOMY

- John G. Rose Jr., MD
- Mark J. Lucarelli, MD
- Bradley N. Lemke, MD

*Department of Ophthalmology and Visual Sciences,
University of Wisconsin–Madison, Madison, Wisconsin*

Proper diagnosis and management of facial cosmetic issues hinge on a thorough understanding of the location of critical structures and the anatomic relation between them. Accurate intraoperative identification of anatomy is fundamental when performing facial cosmetic surgery and for preventing complications.

FOREHEAD AND EYEBROW

As a major determinant of facial expression and an important source of support for the eyelids, the eyebrows should be included in any evaluation of eyelid dysfunction. Eyebrow position strongly influences eyelid position and architecture; and many cases of upper eyelid ptosis and apparent dermatochalasis are, in fact, a consequence of eyebrow ptosis. Similarly, frontalis muscle recruitment can mask significant blepharoptosis. In these situations, addressing only the lids may lead to an inadequate or undesirable surgical result.

The ideal contour of the eyebrows (Fig. 1-1) varies according to age and gender. The female medial brow generally begins superior, or slightly superonasal, to the medial canthus; and the lateral brow ends superotemporal to the lateral canthus, at the end of a line extending from the most lateral extent of the ala of the nose through the lateral canthus.¹ The medial and lateral ends of the brow are typically at the same vertical level, although the lateral brow may be slightly higher. The apex should lie above the region between the lateral limbus and the lateral canthus.² The male eyebrow generally rides lower and flatter than that of the female eyebrow.³

Eyebrow contour and position are influenced by five principal forehead muscles: frontalis, orbicularis, corrugator, procerus, and depressor supercilii. Contraction of the frontalis elevates the eyebrows, and contraction of the orbicularis depresses them. The corrugator depresses the medial eyebrows toward the midline and forms the vertical furrows in the glabella. The procerus depresses the glabella and forms horizontal wrinkles across the dorsum of the nose. The depressor supercilii also depresses the eyebrows medially, contributing to the formation of oblique glabellar wrinkles. Cook et al.⁴ demonstrated that the depressor supercilii originates in either one or two heads that separate the angular vessels. The frontalis lies approximately 3 mm deep to the skin, and the eyebrow depressors lie approximately 5 mm deep to the skin.⁵

Underneath the eyebrow lies the eyebrow fat pad or retroorbicularis oculi fat (ROOF), which supports the eyebrow over the supra-orbital ridge. Dense, fibrous attachments anchor the ROOF to the supraorbital ridge. Because the ridge underlies only the medial one-third to one-half of the eyebrow, the lateral eyebrow lacks the same degree of underlying support. This has been proposed as an explanation for the fact that the lateral eyebrow often droops more than the medial eyebrow with age.⁶



FIGURE 1-1. Topographic eyelid and eyebrow anatomy in the adult female. The eyebrow is gently arched, with the highest point above the temporal limbus. The highest point to the upper eyelid is slightly nasal to the center of the pupil; the lower eyelid margin lies at the inferior limbus.

EYELIDS

Topography

Eyelid topography (Fig. 1-1) is influenced by age, race, ethnicity, and surrounding facial anatomy, particularly that of the eyebrow. In most individuals, the lateral canthus sits 2 mm higher than the medial canthus, with slightly more elevation in individuals of Asian descent. The adult interpalpebral distance measures 28–30 mm horizontally and 9–12 mm at its greatest vertical extent centrally. The

upper eyelid margin rests approximately 1–2 mm below the superior limbus. The lower eyelid margin rests at or slightly above the inferior limbus. Laxity of the canthal ligaments not only causes poor apposition of the eyelids to the globe, it also changes the contour of the interpalpebral fissure. The upper eyelid is gently curved, with the highest point nasal to the center of the pupil.^{7,8}

The upper eyelid crease is an important surgical landmark, as it is often an incision site. The crease is formed by the superficial insertions of the levator aponeurosis⁹ and should generally be re-formed if these attachments are disturbed.¹⁰ It rides parallel to the lid margin and lies 8–11 mm above the eyelid margin in women and 7–8 mm in men.⁸ In people of European ancestry, the septum-levator insertion occurs 2–5 mm superior to the upper edge of the tarsus.¹¹ In Asians, the orbital septum inserts lower on the levator aponeurosis, below the superior tarsal border,^{11,12} yielding a low or generally less well defined lid crease.¹³ This is an important point to keep in mind when operating on Asian eyelids.

The lower eyelid crease is less prominent. It begins medially 4–5 mm below the lower eyelid margin. It slopes inferiorly as it proceeds laterally. It is formed by fibers that extend anteriorly from the capsulopalpebral fascia into the subcutaneous tissues.¹⁴

Skin and Margin

The eyelid skin is the thinnest in the body, mainly owing to its attenuated dermis. Eyelid incisions therefore heal rapidly. The thinness of the skin also helps keep scarring to a minimum. As it crosses over the orbital rim, the eyelid skin abruptly thickens.

The surface of the eyelid margin contains numerous important anatomic landmarks (Fig. 1-2) for eyelid surgery. The upper eyelid margin has approximately 100 eyelashes, and the lower has about 50. Several sebaceous Zeiss glands empty into each lash follicle, and Moll sweat glands are located between the follicles. Posterior to the lash line on the eyelid margin is the easily noticeable line of meibomian glands, which emanate from the edge of the tarsus. Between the lash line and the meibomian line lies a faint gray line, which is more pronounced in young individuals. This represents the edge of the muscle of Riolan, a striated muscle in the same plane as, but distinct from, the orbicularis oculi.¹⁵ The gray line serves as an important surgical landmark, separating the eyelid vertically into the anterior lamella (skin and orbicularis) and the posterior lamella (tarsus, retractors, and conjunctiva).¹⁶

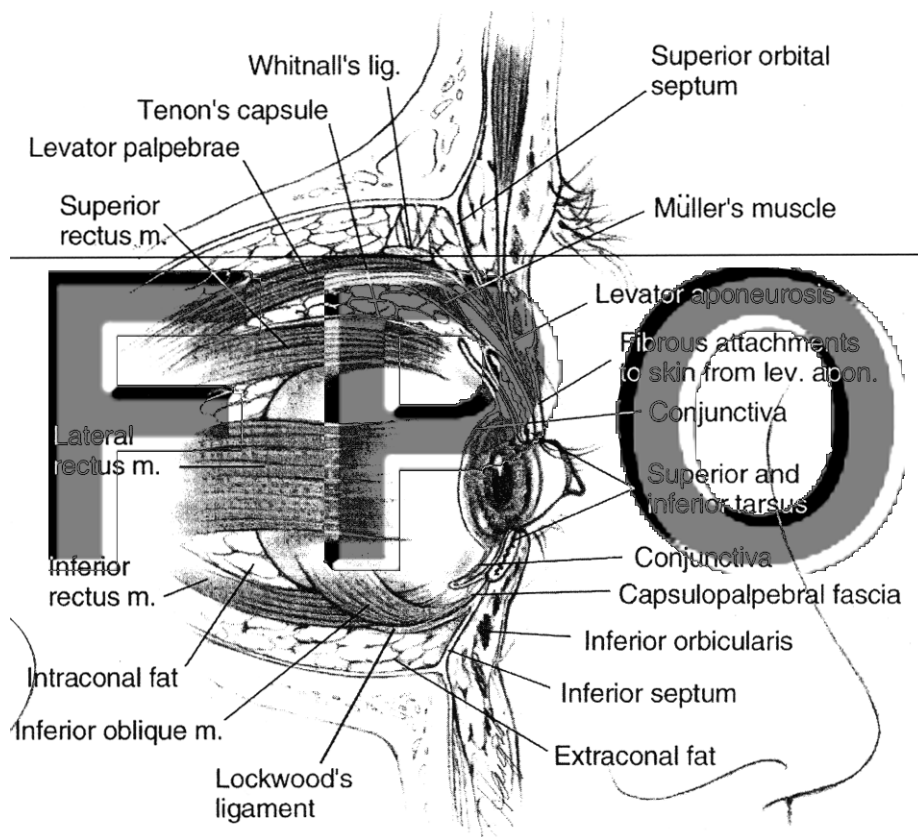


FIGURE 1-2. Parasagittal section of the orbit, showing eyelid structures.

Connective Tissue

The orbital septum (Fig. 1-2) is the boundary between the eyelids and the orbit. It is commonly encountered during eyelid surgery and is easily identified by tugging inferiorly on it to confirm its strong attachment to the orbital rim. The orbital septum is a multilamellar layer of dense connective tissue that lines the orbit and terminates by fusing at the periosteum of the orbital rim. This termination forms the arcus marginalis.¹¹ Laterally, the septum inserts anteriorly onto the lateral canthal ligament and posteriorly on Whitnall's tubercle on the lateral orbital rim. Medially, the septum splits and inserts in both the posterior and anterior lacrimal crest. Multiple fibrous attachments emanate from the orbital septum, anchoring it anteriorly to the orbicularis muscle.¹⁷ The preaponeurotic fat lies immediately posterior to the orbital septum. In the lower eyelid, the orbital sep-

tum fuses with the capsulopalpebral fascia 5 mm inferior to the lower border of the tarsus.¹⁴ In addition, in many Asians a subcutaneous fat pad exists anterior to the septum.¹⁸

The strength of the orbital septum varies among individuals and with age. With time, the septum attenuates, resulting in anterior prolapse of orbital fat.^{8,19}

The tarsal plates (Fig. 1-2) provide rigidity to the eyelids. They are composed of dense, fibrous connective tissue. The upper tarsus measures 10–12 mm vertically, and the lower measures 3–5 mm.²⁰ The tarsal borders adjacent to the lid margin are straight, whereas the opposite edges have a convex curvature. The posterior edge of the tarsus is firmly attached to the palpebral conjunctiva, which extends onto the eyelid margin and terminates at the gray line.

Within the tarsus lie branched, acinar, sebaceous glands with long central ducts. Known as the meibomian glands, they open at the eyelid margin just posterior to the gray line and secrete the oily layer of the tear film. There are about 25 in the upper eyelid and 20 in the lower.¹¹ Inflammation of these glands, known as meibomitis, may, over a long term, result in distichiasis,²¹ or abnormal hair follicles that, unlike the normal eyelashes, curve inward toward the globe, causing discomfort and possibly corneal abrasion. A common treatment for distichiasis, electrohyfrecaction, may cause focal necrosis of the tarsus, resulting in notching at the eyelid margin.⁸ Similarly, excessive cryotherapy for distichiasis can cause a wider-than-planned area of lash loss and scarring.

Emanating from the medial and lateral borders of the tarsi and anchoring them to the orbital rim are the canthal ligaments. They are formed by a confluence of the upper and lower crura, the extensions of the margins of the upper and lower tarsi, respectively. They support not only the tarsi but also the orbicularis. The medial canthal ligament splits into three arms: anterior, posterior, and superior. The anterior arm attaches to the maxillary bone, anterior to the lacrimal crest; the posterior arm attaches to the posterior lacrimal crest^{22,23}; and the superior arm inserts onto the orbital process of the frontal bone.²⁴ The lateral canthal ligament inserts 3–4 mm inside the lateral orbital rim at Whitnall's tubercle, on the zygomatic bone.^{25, 26} During lower eyelid-tightening procedures, which usually involve surgical manipulation of the lateral aspect of the lower tarsus and the lateral canthal ligament, the posterior direction and periosteal insertion of the lateral canthal ligament must be reestablished. Laxity of the canthal ligaments can cause ectropion, as well as cosmetically apparent shortening of the horizontal palpebral fissure.²⁷

An important support for the upper eyelid is Whitnall's ligament. Its role has been debated; it may serve as a fulcrum-like check ligament for the levator or as a swinging suspender, providing vertical support for the upper eyelid.^{17,28,29} Despite this debate, it is understood that Whitnall's ligament suspends the lacrimal gland, superior oblique ligament, levator muscle (with the primary support for the levator coming from the globe), and Tenon's capsule. Whitnall's ligament is a transverse fibrous condensation that inserts medially inside the superomedial orbital rim on the frontal bone at the trochlea and laterally inside the superolateral orbital rim, near the frontozygomatic suture, where it fuses with fibers of the lacrimal gland capsule. It encircles the levator complex³⁰ at the level of the junction of the levator muscle and the fibrous levator aponeurosis. The aponeurosis extends another 14–20 mm inferior to Whitnall's ligament to insert on the lower third of the anterior face of the upper tarsus. Dehiscence of the levator aponeurosis is responsible for most cases of involutional ptosis.

Musculature

The orbicularis oculi muscle (Fig. 1-2) surrounds the anterior orbit and can be divided into three components: pretarsal, preseptal, and orbital.³¹ The pretarsal orbicularis originates from the anterior and posterior arms of the medial canthal ligament, and it is firmly adherent to the anterior face of the tarsi. Medially, the pretarsal orbicularis divides into a superficial head, which surrounds the canaliculi, and a deep head, which inserts on the posterior lacrimal crest and lacrimal fascia. These insertions allow the pretarsal orbicularis to play an important role in the lacrimal pump mechanism. The preseptal orbicularis originates from the upper and lower margins of the medial canthal ligament and inserts lateral to the orbital rim on the zygoma. It overlies the orbital septum and orbital rim; it is separated from the septum by a fibrofatty layer, the postorbicular fascia.⁸ This layer is an important surgical dissection plane. The orbital orbicularis originates from the maxillary and frontal bones, as well as from the medial canthal ligament; it overrides the orbital rims and inserts at the same location as the preseptal orbicularis. The latter two portions of the orbicularis are responsible for forced eyelid closure.

Two important components of the orbicularis are the muscle of Riolan and Horner's muscle. The muscle of Riolan is a small segment of the orbicularis that is separated from the pretarsal orbicularis by the eyelash follicles.¹⁵ It corresponds to the gray line seen at the eye-

lid margin.¹⁶ The deep pretarsal head of the orbicularis is known as Horner's muscle. Contraction of this muscle pulls the eyelids medially and posteriorly. In so doing, Horner's muscle compresses the canaliculi and lacrimal ampullae, pushing tears toward the lacrimal sac and, at the same time, creating negative pressure within the lacrimal sac.³² This mechanism, known as the lacrimal pump,³³ can therefore be compromised by weakening or laxity of the eyelids, resulting in epiphora.³⁴

The main retractor of the upper eyelid is the levator palpebrae superioris (Fig. 1-2). It originates at the superior edge of the annulus of Zinn in the orbital apex and courses anteriorly through the superior orbit, along the superior aspect of the superior rectus muscle. As it approaches the upper eyelid, the levator is encircled by Whitnall's ligament.³⁰ At this point, the levator muscle transitions into the fibrous levator aponeurosis, which courses inferiorly for another 14–20 mm, where the posterior one-third of the lamellae attach to the inferior third of the anterior surface of the tarsus. Also at the level of Whitnall's ligament, the levator sends off lateral and medial horns. The lateral horn attaches to the zygomatic bone. The medial horn fuses with the posterior arm of the medial canthal ligament and inserts on the posterior lacrimal crest. The lateral and medial horns help ensure that the upper eyelid maintains a curvature that keeps it apposed to the globe during opening.⁷ The anterior two-thirds of the lamellae of the levator aponeurosis sends fibers anteriorly through the septum and orbicularis to the skin; these insertions form the upper eyelid crease.⁹

Aging affects both the levator muscle and the aponeurosis. Age-related thinning and dehiscence of the aponeurosis from the tarsus is a common cause of involutional ptosis.^{35,36} In addition, the muscle belly can become infiltrated with fat and connective tissue.⁸

Underlying the levator aponeurosis and attached to it via loose connective tissue is Müller's muscle, which is sympathetically innervated and composed of smooth muscle fibers. It originates from the undersurface of the levator and courses inferiorly for approximately 15 mm to insert with elastic fibers onto the superior edge of the tarsus in the upper eyelid. A lateral extension of Müller's muscle divides the lacrimal gland into its two lobes.³⁷ It is generally accepted that Müller's muscle is a secondary transmitter of lift to the upper eyelid, as evidenced by the 2- to 3-mm ptosis seen either in sympathetic denervation syndromes, such as Horner's syndrome, or in the normal fatigue-related decrease in sympathetic tone. One group has suggested that Müller's muscle may serve as a primary transmitter of levator muscle tone to the tarsal plate.³⁸

Less well defined than their counterparts that elevate the upper eyelid, the lower eyelid retractors—capsulopalpebral fascia and inferior tarsal muscle—are palpebral extensions of the inferior rectus muscle. The inferior rectus muscle, through these lower eyelid retractors, is responsible for the full extent of depression of the lower eyelid during downgaze.⁸ A fibrous extension of the inferior rectus muscle, the capsulopalpebral head of the inferior rectus wraps around the inferior oblique muscle, at which point the capsulopalpebral head splits into inferior and superior divisions. The inferior division, which is the capsulopalpebral fascia, then rejoins the superior division, the inferior tarsal muscle,¹⁴ which, like Müller's muscle, is composed of smooth muscle fibers. These two layers are not generally distinct during surgical dissection.

The lower eyelid retractors have three insertions. Posteriorly, the retractors insert on Tenon's fascia. Centrally, the inferior tarsal muscle fibers terminate a few millimeters inferior to the tarsus,¹⁴ and a fibrous continuation attaches to the inferior border of the tarsus. Anteriorly, the capsulopalpebral fascia fuses with the orbital septum 4 mm inferior to the tarsus. Fibers continue through the septum and attach to the subcutaneous tissue, forming the lower eyelid crease.⁷

Eyelid Fat Pads

The eyelid fat pads (Fig. 1-2) play an important role in the appearance and contour of the eyelids. In the youthful face, this anterior orbital fat imparts a fullness and smoothness to the upper and lower eyelids. With age, atrophy of eyelid fat can cause the eyelids to sink posteriorly, resulting in involutional enophthalmos and a lid crease displaced away from the lid margin.²⁷ In addition, weakening of the orbital septum can allow anterior prolapse of the anterior orbital fat, resulting in puffy-appearing eyelids, known as steatoblepharon.¹⁹

The upper eyelid contains two fat pads, separated by the trochlea and superior oblique tendon, which are located posterior to the orbital septum and immediately anterior to the levator muscle and aponeurosis. This anatomic relation is a reliable guide for the eyelid surgeon who wishes to combine levator aponeurosis repair with blepharoplasty, fat pad excision, or both. This region of the upper eyelid is divided into three fibrous compartments. The medial and central compartments contain the medial and preaponeurotic fat pads,³⁹ and the lateral compartment contains the lacrimal gland. Care must be taken not to confuse the lacrimal gland with eyelid fat in the upper eyelid. The lacrimal gland, which sits lateral to the two upper eyelid fat pads,

appears pink and firm, in contrast to the glistening, yellow, loose-appearing fat in the central preaponeurotic pad and the whiter, more fibrous nasal fat pad.

The lower eyelid contains three fat pads that are enclosed in three fibrous compartments: medial, central, and lateral. The inferior oblique muscle courses between the medial and central compartments in the lower eyelid; and the central and lateral fat pads are separated by a fibrous accurate extension passing from the inferior oblique to the inferior lateral orbital wall. Because the eyelid fat pads are anterior projections of orbital fat, care must be taken intraoperatively not to cause excessive traction, as orbital hemorrhage may result during the intra- or postoperative period.

Eyelid Vasculature

Eyelid blood supply (Fig. 1-3) arises from both the external and internal carotid arteries. The external carotid artery gives rise to the facial artery, the superficial temporal artery, and the infraorbital artery. As it courses across the face diagonally toward the nasolabial folds, the facial artery becomes the angular artery, which lies directly underneath the orbicularis and feeds the vascular arcades of the eyelids at the medial canthus. The internal carotid artery gives rise to the ophthalmic artery, which in turn terminates as the lacrimal, frontal, supraorbital, supratrochlear, and nasal arteries. Anastomoses between the angular, lacrimal, and supratrochlear arteries form the superior marginal arcade and superior peripheral arcade in the upper eyelid. The angular artery anastomoses in the lower eyelid with the infraorbital and zygomaticofacial arteries to form the inferior marginal arcade. A poorly developed inferior peripheral arcade is present in some individuals.^{7,8}

In the upper and lower eyelids, the marginal arcades lie just anterior to the tarsi, 2–4 mm from the eyelid margin. Also in the upper eyelid, the superior peripheral arcade lies just anterior to Müller's muscle, superior to the tarsus. This arcade not only serves the upper part of the upper eyelid it supplies the superior conjunctival fornix and communicates with the anterior ciliary vessels near the limbus. Dissection in the plane of Müller's muscle can cause hemorrhage from this arcade.⁸

The facial vein is the principal venous drainage source for the eyelids. It courses superficial and lateral to the facial artery. It begins near the medial canthus as the angular vein and anastomoses with the superior ophthalmic vein via the supraorbital vein.

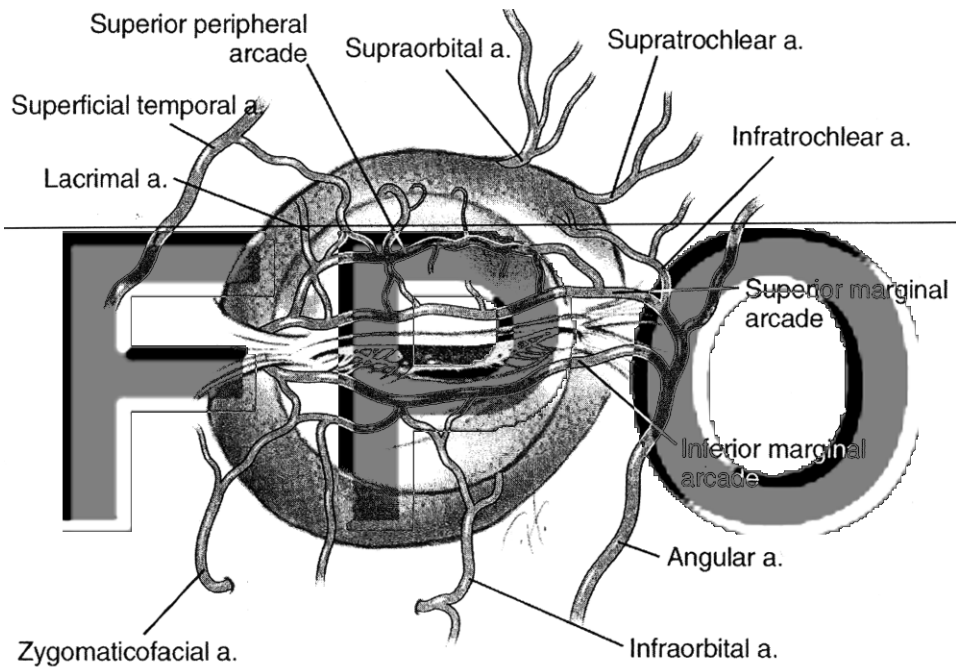


FIGURE 1-3. Arterial blood supply to the eyelids.

Lymphatic drainage of the eyelids has been somewhat elusive, but a study by Cook et al.^{40,41} demonstrated in a primate model that the entire upper eyelid drains to the parotid lymph nodes, with additional drainage from the medial upper eyelid to the submandibular lymph nodes. The medial canthus and lateral lower eyelid drain to the parotid lymph nodes. The central and medial lower eyelid drain to the submandibular lymph nodes.

Innervation

The eyelids are innervated by the facial nerve [cranial nerve (CN) VII], oculomotor nerve (CN III), trigeminal nerve (CN V), and sympathetic fibers from the superior cervical ganglion. Sensory innervation to the upper eyelid is provided by the ophthalmic division of the trigeminal nerve (CN V₁), which has three branches—lacrimal, frontal, nasociliary—all of which enter the orbit via the superior orbital fissure. The lacrimal nerve supplies the lacrimal gland conjunctiva and lateral upper eyelid, and it sends off a branch that anastomoses with the zygomaticotemporal nerve. The frontal nerve

courses anteriorly between the periorbital and levator, dividing into the supraorbital and supratrochlear nerves. The supratrochlear nerve innervates the medial upper eyelid and forehead, and the two divisions of the supraorbital nerve innervate most of the remainder of the forehead. A superficial division passes anterior to the frontalis muscle to innervate the forehead skin, and a deep division passes laterally anterior to the pericranium and supplies the frontoparietal scalp.⁴² The nasociliary branch gives rise to the posterior and anterior ethmoidal nerves, two or three long ciliary nerves to the globe, a sensory root to the ciliary ganglion, and the infratrochlear nerve.⁸

Sensory innervation to the lower eyelid is provided by the maxillary branch of the trigeminal nerve (CN V₂). The zygomatic branch from V₃ divides into the zygomaticofacial and zygomaticotemporal nerves. The zygomaticofacial nerve courses along the inferolateral orbit, passes through the zygomaticofacial foramen, and supplies the skin of the cheek. The zygomaticotemporal nerve exits the orbit into the temporal fossa, innervating the lateral forehead. The infraorbital nerve, a continuation of V₂, exits via the infraorbital foramen, yielding several terminal branches—inferior palpebral, lateral nasal, and superior labial nerves—which supply the skin and conjunctiva of the lower eyelid, the skin and septum of the nose, and the skin and mucosa of the upper lip, respectively.⁸

Motor innervation to the levator muscle comes from the superior division of the oculomotor nerve (CN III). This division courses within the muscle cone of the orbit, entering the superior rectus from its inferior aspect, 15 mm from the orbital apex. At this point, it also sends off terminal fibers, which pass around or through the medial aspect of the superior rectus to innervate the levator.

The frontalis and orbicularis muscles are innervated by divisions of the facial nerve (Fig. 1-4). After originating at its nucleus in the pons, the facial nerve leaves the facial canal via the stylomastoid foramen. It then passes through the parotid gland and gives rise to several divisions: temporal, zygomatic, buccal, mandibular, and cervical nerves. The temporal branch innervates the frontalis muscle and is one of the most commonly injured nerves during forehead and temporal surgical dissection. The temporal, zygomatic, and buccal divisions all contribute innervation to the orbicularis oculi, with significant overlap of the regions innervated by each nerve.

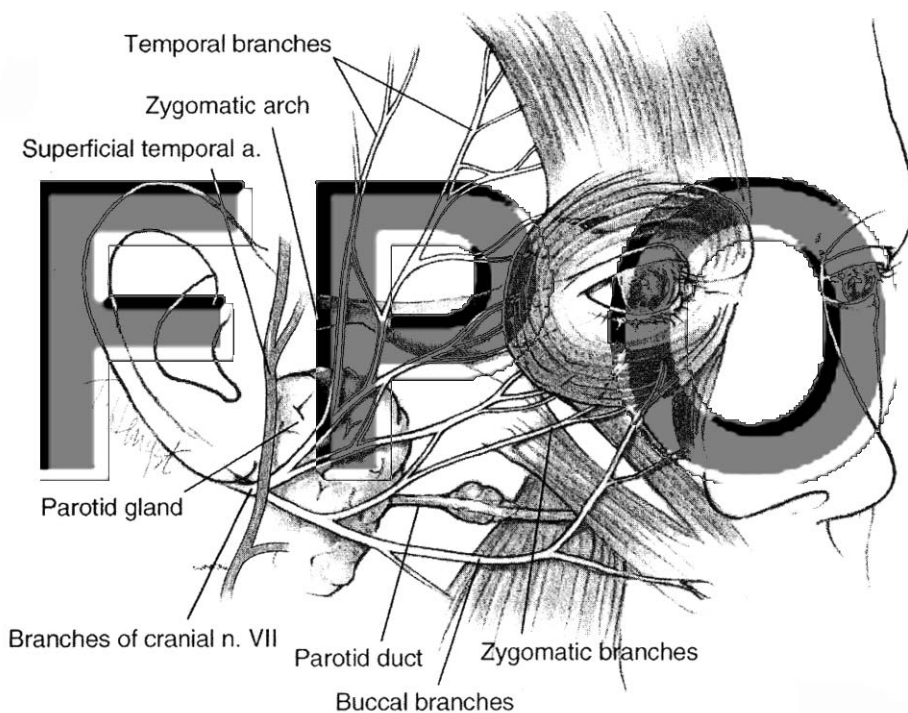


FIGURE 1-4. Anatomy of the facial nerve (cranial nerve VII).

MID-FACE AND LOWER FACE

Osteology

The topography of the mid-face is determined to a significant extent by the bony anatomy. The facial bones are demarcated from the bones of the cranium at the level of the orbits. The superior extent of the mid-face is the zygomaticofrontal suture, and the teeth form the inferior border. The posterior border is defined by the sphenothmoid junction and the pterygoid plates.

Most of the mid-facial bones extend from the borders of the orbit. The zygoma, which forms the lateral facial buttress, and the greater wing of the sphenoid together form the lateral orbital wall. The medial orbital wall includes the ethmoid, lacrimal, sphenoid, and maxillary bones. Associated with them are the bony nasal turbinates. The maxilla extends from the inferior portion of the medial wall to the orbital floor and extends inferiorly to form the anterior bony surface of the mid-face until giving rise to the upper teeth. The contour of the maxilla has recently been shown to undergo characteristic changes

with age.⁴³ The palatine bone, at its superior extent, forms the posterior orbital floor and extends inferiorly into the posterior mid-face.

The mandible provides skeletal support to the lower face. It forms a synovial joint with the skull at the condyles; the muscles of mastication stabilize this joint.

A series of studies by Pessa et al. indicated that the facial bones remodel throughout adulthood and are partly responsible for the aging changes seen in the mid-face. Specifically, the orbital rim appears to move posteriorly with respect to the plane of the cornea,⁴⁴ and the maxillary arch and the orbital aperture curvature increase with age.^{43,45}

Skin and Subcutaneous Tissues

The facial skin and subcutaneous tissues vary in thickness, texture, color, and mobility, dividing the face into the aesthetic units discussed in this chapter. The skin consists of three layers: epidermis, dermis, and subcutaneous tissue. The epidermis consists of keratinized, stratified, squamous epithelium. The underlying dermis is divided into a superficial papillary dermis comprised of randomly oriented collagen fibrils and a deeper reticular dermis, which is vascularized and has collagen fibrils oriented parallel to the epidermal surface.⁴⁶ The underlying subcutaneous fibrofatty layer varies in thickness among individuals and facial aesthetic units, with the cheeks, temples, and neck being the thickest.

Age-related changes in the skin are usually seen in conjunction with photodamage. They include loss of elasticity, atrophy of subcutaneous fat, and pigmentary changes.⁴⁷

Connective Tissue

The predominant connective tissue layer in the midface is the superficial musculoaponeurotic system (SMAS) (Fig. 1-5). First described more than 25 years ago,⁴⁸ the SMAS has been suggested to be a transmitter and distributor of facial muscular contractions to the skin and a key structure in the development of mid-face ptosis. Further anatomic study has characterized the SMAS in the periocular and mid-face regions.^{49,50} In recent years, the SMAS has been identified as an important structure in facial rhytidectomy, and the SMAS-invested muscles are recognized as targets for facial soft-tissue augmentation.⁵

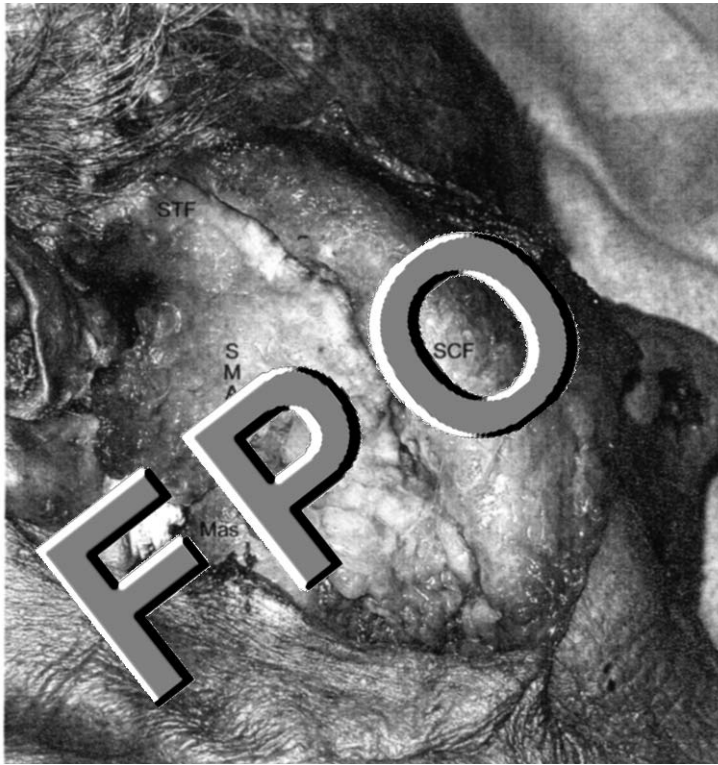


FIGURE 1-5. Human cadaver dissection of the mid-face. Skin and subcutaneous fat (SCF), also known as the malar fat pad in this region, are reflected anteriorly via a preauricular incision, revealing the superficial musculoaponeurotic system (SMAS), which is continuous with the superficial temporalis fascia (STF) and lies superficial to the masseter muscle (Mas).

Structurally, the SMAS is a fibromuscular plane that divides the parotid and cheek fat into two layers.⁴⁸ It invests the zygomaticus major, zygomaticus minor, and levator labii superioris⁵ and lies 11–13 mm deep to the skin at mid-cheek.⁵¹ It is continuous with the frontalis in the upper face, the platysma in the lower face,^{52–57} and the anterior and posterior orbicularis fascia⁵⁰ in the orbital region. The major vessels and nerves, including the motor branches of the facial nerve, lie deep to the SMAS and send perforating branches anteriorly through it.

The following soft tissue attachments support the SMAS: the parotid fascia, the masseteric fascia via masseteric cutaneous ligaments,⁴⁹ the platysma via platysma auricular ligaments and anterior

platysma cutaneous ligaments,⁵⁸ and the zygomatic major and minor muscles via their bony attachments. Bony attachments are at the zygomatic arch^{48,55} and the mandible,⁵⁸ as well as at the inferior orbital rim via the orbitomalar ligament,⁵⁰ which in turn sends fibers anteriorly to the skin to form the nasojugal fold.

The SMAS is subject to age-related changes, which are in large part responsible for mid-face ptosis. Lucarelli et al.⁴⁹ demonstrated age-related attenuation of the orbitomalar, masseteric cutaneous, and zygomatic ligaments, which support the SMAS and associated malar and buccal fat pads. Cutaneous projections of the orbitomalar ligament help form the nasojugal and malar skinfolds; increased traction on the ligament by a descended SMAS may be partly responsible for the accentuation of the nasojugal and malar skin folds that appear with age.⁵⁰ Involutional descent of the malar fat pad, which attaches to the superficial surface of the SMAS, results in increased prominence of the nasojugal fold.^{59–61} A recent outcomes study by Hamra⁶² indicated that the malar fat pad may continue to descend more rapidly than the SMAS following facelift surgery.

Musculature

The muscles of facial expression are flat muscles that have high variability from one individual to another. Freilinger et al.⁶³ reported in 1987 the three-dimensional arrangement of these muscles in the mid-face and lower face, dividing the muscles into four layers. The first and most superficial layer includes the orbicularis oculi, zygomaticus minor, and depressor anguli oris. The second layer includes the zygomaticus major, levator labii superioris nasae et alae, platysma, risorius, and depressor labii inferioris. Progressing deeper, the third layer includes the orbicularis oris and levator labii superioris. The fourth and deepest layer includes the mentalis, levator anguli oris, and buccinator. The facial nerve branches travel between the third and fourth layers, innervating the first three layers from below and the fourth layer from above. Subsequent study has shown the zygomaticus major, zygomaticus minor, and levator labii superioris all to be invested in the SMAS,⁵¹ illustrating an evolving understanding of the muscular anatomy of the mid-face.

The muscles of mastication include the masseter and temporalis, with two associated muscles: the buccinator and orbicularis oris. The orbicularis oris acts as a sphincter at the mouth, and the buccinator provides medially directed tension on the cheeks, keeping food in the center of the mouth. The masseter originates at the zygomatic arch

and inserts in the mandible. The temporalis inserts at the temporalis fossa and at the medial mandibular ramus and coronoid process. The temporalis is covered by a tough fascia, the deep temporalis fascia. Superior to the zygomatic arch, the superficial temporalis fascia arises and is separated from the deep temporalis fascia by the superficial temporal fat pad. The superficial temporalis fascia is continuous with the SMAS. Densely adherent to the deep aspect of the superficial temporal fascia is the temporal branch of the facial nerve; dissection in this region must therefore be deep to the superficial temporalis fascia, in the plane of the deep temporalis fascia, to avoid injuring the nerve.

Mid-face Fat Pads

Apart from the suborbicularis oculi fat pad (SOOF) described above, the principal fat pads of the mid-face are the malar and buccal fat pads. The malar fat pad comprises the subcutaneous fat in the cheek and is continuous with both the jowl fat underneath the jawline⁶⁰ and the SOOF.⁴⁹ The buccal fat pad rests deeper in the face, bounded medially by the buccal mucosa, with buccal, temporal, and pterygoid extensions.^{64,65} This sub-SMAS fat in the malar region has been demonstrated to be continuous with the ROOF fat.⁵⁰

Although frequently postulated as a rationale for facial soft tissue augmentation,^{66–70} few studies since the initial work of Gonzalez-Ulloa and Flores⁷¹ have demonstrated actual volume loss of facial fat and muscles with age.

Facial Vasculature

The facial vasculature arises from the internal and external carotid arteries. The first branch of the internal carotid artery is the ophthalmic artery, which supplies the eyelids, forehead, and dorsum of the nose. The forehead is supplied by the supraorbital and supratrochlear arteries. The eyelids are vascularized by the infraorbital, palpebral, and marginal arteries. The nose is supplied by the anterior and posterior ethmoid arteries.

The external carotid artery branches into the facial, internal maxillary, and superficial temporal arteries. The facial artery supplies the lips via the superior and inferior labial arteries, as well as the lateral nose and nasal dorsum, with anastomoses to the anterior and posterior ethmoidal arteries. Because of these anastomoses, high-pressure injection of steroids or soft-tissue fillers can result in retro-

grade flow, embolization of the ophthalmic artery or central nervous system vasculature, and ultimately blindness^{72–74} or stroke.^{75,76} The internal maxillary artery gives off the infraorbital artery, which enters the orbit at the infraorbital fissure and courses along the infraorbital groove, exiting the orbit at the infraorbital foramen to supply the lower eyelid. Care must be taken not to damage the infraorbital artery and associated nerve during surgical dissection along the orbital floor and inferior orbital rim. The superficial temporal artery branches from the external carotid artery in the parotid gland. At the level of the zygomatic arch, it gives off the transverse facial artery to supply the lateral canthal area. Superior to the zygomatic arch, the superficial temporal artery travels within the plane of the SMAS and gives off the middle temporal artery, which supplies the superficial temporal fat pad and temporalis muscle. Terminal branches of the superficial temporal artery supply the parietal area and forehead, with anastomoses to the supraorbital and supratrochlear arteries.

Facial Innervation

Motor innervation to the mid-face and lower face is via the facial nerve (CN VII). After exiting the stylomastoid foramen, it enters the parotid gland, where it divides into its main branches: temporal, zygomatic, buccal, mandibular, and cervical. The two most subject to surgical injury are the temporal and mandibular nerves.

The temporal nerve exits the parotid gland at its superior border and travels superiorly on the underside of the SMAS to reach the underside of the superficial temporalis fascia superior to the zygomatic arch.⁶³ Dissection in this region must therefore be deep to the SMAS and superficial temporalis fascia to avoid damage to the temporal nerve.

The mandibular nerve, also at risk for surgical injury, passes superior and parallel to the inferior border of the mandible, deep to the platysma. As it courses medially, it becomes more superficial to innervate the depressor labii superioris and depressor anguli oris posteriorly.⁷⁷ Although the mandibular nerve is protected during sub-SMAS dissection laterally, it is subject to injury from medial dissection along the mandible.

Sensory innervation to the face is via the three divisions of the trigeminal nerve (CN V): ophthalmic nerve, maxillary nerve, and sensory mandibular branch. The ophthalmic nerve serves the forehead, upper eyelids, scalp, and dorsum of the nose. Careful attention during dissection in the regions of the supraorbital and supratrochlear

foramens prevents injury to these nerves during browlift procedures. The maxillary nerve serves the mid-face, from the lower eyelids to the upper lip. Dissection in the region of the infraorbital foramen during subperiosteal mid-face lifts can result in cheek paresthesia if the infraorbital nerve is injured. The mandibular branch innervates the lower lip, mandible, and temples; a motor branch provides motor innervation to the temporalis, masseter, and medial and lateral pterygoid muscles.

REFERENCES

1. Westmore MG. *Facial cosmetics in conjunction with surgery*. Presented at the *Aesthetic Plastic Surgical Society Meeting*, Vancouver, BC, 1975.
2. Gunter JP, Antrobus SP. *Aesthetic analysis of the eyebrows*. *Plast Reconstr Surg* 1997;**99**:1808–1816.
3. Bosniak SL, Zilkha MC. *Cosmetic blepharoplasty and facial rejuvenation*. Philadelphia: Lippincott-Raven, 1999.
4. Cook BE, Lucarelli MJ, Lemke BN. *The depressor supercilii muscle: anatomy, histology, and cosmetic implications*. *Am J Cosmetic Surg* 2000;**17**:193–205.
5. Rose J, Lemke BN, Lucarelli MJ, et al. *Anatomy of facial recipient sites for autologous fat transfer*. *Am J Cosmetic Surg* 2003;**20**(1):17–25.
6. Lemke BN, Stasior OG. *The anatomy of eyebrow ptosis*. *Arch Ophthalmol* 1982;**100**:981–986.
7. Tarbet KJ, Lemke BN. *Clinical anatomy of the upper face*. *Ophthalmol Clin* 1997;**37**:11–28.
8. Kikkawa DL, Lemke BN. *Orbital and eyelid anatomy*. In: Dortzbach RK (ed) *Ophthalmic Plastic Surgery: Prevention and Management of Complications*. New York: Raven, 1994.
9. Stasior GO, Lemke BN, Wallow IH, et al. *Levator aponeurosis elastic fiber network*. *Ophthalmic Plast Reconstr Surg* 1993;**9**:1–10.
10. Gavaris P. *The lid crease [editor's note]*. *Adv Ophthalmic Plast Reconstr Surg* 1982;**1**:89–93.
11. Meyer D, Linberg JV, Wobig JL, et al. *Anatomy of the orbital septum and associated eyelid connective tissues: implications for ptosis surgery*. *Ophthalmic Plast Reconstr Surg* 1991;**7**:104–113.
12. Jeong S, Lemke BN, Dortzbach RK, et al. *The Asian upper eyelid: an anatomical study with comparison to the Caucasian eyelid*. *Arch Ophthalmol* 1999;**117**:901–912.
13. Doxanas MT, Anderson RL. *Oriental eyelids: an anatomic study*. *Arch Ophthalmol* 1984;**102**:1232–1235.
14. Hawes MJ, Dortzbach RK. *The microscopic anatomy of the lower eyelid retractors*. *Arch Ophthalmol* 1982;**100**:1313–1318.

15. Lipham W, Tawfik H, Dutton J. *A histologic analysis and three-dimensional reconstruction of the muscle of Riolan.* Ophthalmic Plast Reconstr Surg 2002;**18**:93–98.
16. Wulc AE, Dryden RM, Khatchaturian T. *Where is the grey line?* Arch Ophthalmol 1987;**105**:1092–1098.
17. Anderson RL, Dixon RS. *The role of Whitnall's ligament in ptosis surgery.* Arch Ophthalmol 1979;**97**:705.
18. Uchida J. *A surgical procedure for blepharoptosis vera and for pseudo-blepharoptosis orientalis.* Br J Plast Surg 1962;**15**:271–276.
19. Furnas D. *Festoons, mounds and bags of the eyelids and cheek.* Clin Plast Surg 1993;**20**:367.
20. Wesley RE, McCord CD, Jones NA. *Height of the tarsus of the lower eyelid.* Am J Ophthalmol 1980;**90**:102–105.
21. Scheie HG, Albert DM. *Distichiasis and trichiasis: origin and management.* Am J Ophthalmol 1966;**61**:718–720.
22. Lemke BN, Della Roca RC. *Surgery of the eyelids and orbit: an anatomical approach.* East Norwalk, CT: Appleton & Lange, 1990.
23. Dutton J. *Atlas of clinical and surgical orbital anatomy.* Philadelphia: Saunders, 1994.
24. Anderson RL. *The medial canthal tendon branches out.* Arch Ophthalmol 1977;**95**:2051–2052.
25. Anastassov G, van Damme P. *Evaluation of the anatomical position of the lateral canthal ligament: clinical implications and guidelines.* J Craniofac Surg 1996;**7**:429–436.
26. Whitnall SE. *On a tubercle on the malar bone, and on the lateral attachments of the tarsal plates.* J Anat Physiol 1911;**45**:426–432.
27. Van den Bosch WA, Leenders I, Mulder P. *Topographic anatomy of the eyelids, and the effects of sex and age.* Br J Ophthalmol 1999;**83**:347–352.
28. Whitnall SE. *Anatomy of the Human Orbit.* London: Oxford University Press, 1932.
29. Goldberg RA, Wu JC, Jesmanowicz A, et al. *Eyelid anatomy revisited: dynamic high-resolution images of Whitnall's ligament and upper eyelid structures with the use of a surface coil.* Arch Ophthalmol 1992;**110**:1598.
30. Codere F, Tucker NA, Renaldi B. *The anatomy of Whitnall ligament.* Ophthalmology 1995;**102**:2011–2019.
31. Jones LT. *An anatomical approach to the problems of the eyelids and lacrimal apparatus.* Arch Ophthalmol 1961;**105**:1092–1098.
32. Doane M. *Blinking and the mechanics of the lacrimal drainage system.* Ophthalmology 1981;**88**:844–851.
33. Jones LT. *Epiphora: its causes and new surgical procedures for its course.* Am J Ophthalmol 1954;**38**:824–831.
34. Hill JC. *Treatment of epiphora owing to flaccid eyelids.* Arch Ophthalmol 1979;**97**:323–324.

35. Dortzbach RK, Sutula FC. *Involitional blepharoptosis: a histopathological study*. Arch Ophthalmol 1980;**98**:2045–2049.
36. Jones LT, Quickert MH, Wobig JL. *The cure of ptosis by aponeurotic repair*. Arch Ophthalmol 1975;**93**:629–634.
37. Morton AD, Elnor VM, Lemke BN, et al. *Lateral extensions of the Müller muscle*. Arch Ophthalmol 1996;**100**:1486–1488.
38. Bang YH, Park SH, Kim JH, et al. *The role of Müller's muscle reconsidered*. Plast Reconstr Surg 1998;**101**:1200–1204.
39. Sires BS, Lemke BN, Dortzbach RK, et al. *Characterization of human orbital fat and connective tissue*. Ophthalmic Plast Reconstr Surg 1998;**14**:403–414.
40. Cook B, Lucarelli M, Lemke B, et al. *Eyelid lymphatics. I. histochemical comparisons between the monkey and human*. Ophthalmic Plast Reconstr Surg 2002;**18**(1):18–23.
41. Cook B, Lucarelli M, Lemke B, et al. *Eyelid lymphatics. II. a search for drainage patterns in the monkey and correlations with human lymphatics*. Ophthalmic Plast Reconstr Surg 2002;**18**(2):99–106.
42. Knize DM. *A study of the supraorbital nerve*. Plast Reconstr Surg 1995;**96**:564–569.
43. Zadoo V, Pessa J. *Biological arches and changes to the curvilinear form of the aging maxilla*. Plast Reconstr Surg 2000;**106**:420–426.
44. Pessa J, Desvigne L, Lambros V, et al. *Changes in ocular globe-to-orbital rim position with age: implications for aesthetic blepharoplasty of the lower eyelids*. Aesthetic Plast Surg 1999;**23**:337–342.
45. Pessa J, Chen Y. *Curve analysis of the aging orbital aperture*. Plast Reconstr Surg 2002;**109**:751–755.
46. Obagi S, Bridenstine J. *Lifetime Skincare*. Oral Maxillofac Surg Clin North Am 2000;**12**:531–540.
47. Glogau R. *Physiologic and structural changes associated with aging skin*. Dermatol Clin 1997;**15**:555.
48. Mitz V, Peyronie M. *The superficial musculoaponeurotic system (SMAS) in the parotid and cheek area*. Plast Reconstr Surg 1976;**50**:80.
49. Lucarelli M, Khwarg S, Lemke B, et al. *The anatomy of midfacial ptosis*. Ophthalmic Plast Reconstr Surg 2000;**16**:7–22.
50. Kikkawa D, Lemke BN, Dortzbach R. *Relations of the superficial musculoaponeurotic system to the orbit and characterization of the orbitomalar ligament*. Ophthalmic Plast Reconstr Surg 1996;**12**:77–88.
51. Rose J, Lucarelli MJ, Lemke BN. *Radiologic Measurement of the Subcutaneous Depth of the SMAS in the Midface*. Orlando, FL (Oct. 18–19, 2002): In *Proceedings of American Society of Ophthalmic Plastic and Reconstructive Surgery*, 2002.
52. Gosain A, Yousif N, Madieto G, et al. *Surgical anatomy of the SMAS: a reinvestigation*. Plast Reconstr Surg 1993;**92**:1254–1263.
53. Jost G, Lamouche G. *SMAS in rhytidectomy*. Aesthetic Plast Surg 1982;**6**:69.

54. Ruess W, Owsley J. *The anatomy of the skin and fascial layers of the face in aesthetic surgery*. Clin Plast Surg 1987;**14**:677.
55. Stuzin J, Baker T, Gordon H. *The relationship of the superficial and deep facial fascias: relevance to rhytidectomy and aging*. Plast Reconstr Surg 1992;**89**:441.
56. Thaller S, Kim S, Patterson H, et al. *The submuscular aponeurotic system (SMAS): a histologic and comparative anatomy evaluation*. Plast Reconstr Surg 1990;**86**:690–696.
57. Wassef M. *Superficial fascial and muscular layers in the face and neck: a histologic study*. Aesthetic Plast Surg 1987;**11**:171.
58. Furnas D. *The retaining ligaments of the cheek*. Plast Reconstr Surg 1989;**83**:11.
59. Hamra S. *Lifting the malar fat pad for correcting nasolabial folds*. Plast Reconstr Surg 1994;**93**:661–662.
60. Owsley J. *Elevation of the malar fat pad superficial to the orbicularis oculi muscle for correction of prominent nasolabial folds*. Clin Plast Surg 1995;**22**:279–293.
61. Owsley J, Fiala T. *Update: lifting the malar fat pad for correction of prominent nasolabial folds*. Plast Reconstr Surg 1997;**100**:715–722.
62. Hamra S. *A study of the long-term effect of malar fat repositioning in face lift surgery: short-term success but long-term failure*. Plast Reconstr Surg 2002;**110**:940–951.
63. Freilinger G, Gruber H, Happak W, et al. *Surgical anatomy of the mimic muscle system and the facial nerve: importance for reconstructive and aesthetic surgery*. Plast Reconstr Surg 1987;**80**:686–690.
64. Kahn J, Wolfram-Gabel R, Bourjat P. *Anatomy and imaging of the deep fat of the face*. Clin Anat 2000;**13**:373–382.
65. Stuzin J, Wagstrom L, Kawamoto H, et al. *The anatomy and clinical applications of the buccal fat pad*. Plast Reconstr Surg, 1990;**85**:29–37.
66. Amar R. *Microinfiltration adipocytaire (MIA) au niveau de la face, ou restructuration tissulaire par greffe de tissu adipeux*. Ann Chir Plast Esthet 1999;**44**:593–608.
67. Coleman S. *Facial recontouring with lipostructure*. Facial Cosmetic Surg 1997;**24**:347–367.
68. Coleman S. *Structural fat grafts: the ideal filler?* Clin Plast Surg 2001;**28**:111–119.
69. Donofrio L. *Structural autologous lipoaugmentation: a pan-facial technique*. Dermatol Surg 2000;**26**:1129–1134.
70. Klein A, Wexler P, Carruthers A, et al. *Analysis and treatment of the aging face: treatment of facial furrows and rhytides*. Dermatol Clin 1997;**15**:595–607.
71. Gonzalez-Ulloa M, Flores E. *Senility of the face: basic study to determine its causes and effects*. Plast Reconstr Surg 1965;**36**:239–246.
72. Coleman S. *Complications of fat grafts and structural fillers*. In: *New Techniques in Minimally Invasive Aesthetic Surgery*. Los Angeles, CA (Apr. 12–13, 2002).
73. Ellis P. *Occlusion of the central retinal artery after retrobulbar corticosteroid injection*. Am J Ophthalmol 1978;**85**:352–356.

74. Shafir R, Cohen M, Gur E. *Blindness as a complication of subcutaneous nasal steroid injection*. *Plast Reconstr Surg* 1999;**104**:1180–1182.
75. Feinendegen D, Baumgartner R, Schroth G, et al. *Middle cerebral artery occlusion and ocular fat embolism after autologous fat injection in the face*. *J Neurol* 1998;**245**:53–54.
76. Feinendegen D, Baumgartner R, Vuadens P, et al. *Autologous fat injection for soft tissue augmentation in the face: a safe procedure?* *Aesthetic Plast Surg* 1998;**22**:163–167.
77. Liebman E, Webster R, Gaul J, et al. *The marginal mandibular nerve in rhytidectomy and liposuction surgery*. *Arch Otolaryngol Head Neck Surg* 1988;**114**: 179–181.

ENDOSCOPIC FOREHEADPLASTY

The positioning of the eyebrow is important for maintaining periorbital symmetry that is aesthetically pleasing to the human eye. Many authors have described formulas for positioning the “ideal” brow, but in reality this depends on the patient’s characteristics. Each person has unique physical attributes that make him or her attractive, and there is no formula that can encompass these factors. The surgeon must look at each eyebrow on an individual basis.

ETIOLOGY

The positioning of the eyebrow is affected by such factors as brow elevator and depressor muscles, genetics, gravity, skin laxity, surgery, trauma, and the patient’s expressivity. All or some of these factors result in brow ptosis. Although each eyebrow has its own shape, position, and contour, in general the female eyebrow should lie approximately at or above the superior orbital rim. It should have a curve with the tail of the brow higher than the head of the brow. The male eyebrow should be at the level of the superior orbital rim with a less curved configuration. When planning brow surgery, the imbalance between the elevators (frontalis muscle) and the depressors (orbicularis oculi, depressor supercilii, corrugators, procerus) must be addressed.

The frontalis muscle originates at the skin and superficial fascia of the orbicularis muscle. It inserts into the galea aponeurotica. The

main function of the frontalis muscle is to elevate the eyebrows, and it is responsible for the transverse rhytids in the forehead. The corrugator muscle originates at the medial orbital rim and inserts into the frontalis muscle and skin of the eyebrow. It primarily elevates the head of the brow, with descent of the tail. It is responsible for the glabellar frown lines. The orbicularis oculi muscle originates at the medial orbital rim and medial canthal tendon and inserts on the medial aspect of the bony orbit. It depresses the total brow and is responsible for vertical rhytids. The depressor supercilii muscle also originates at the medial orbital rim and medial canthal tendon, and it inserts on the medial aspect of the bony orbit. It is responsible for depressing the head of the brow. The procerus muscle originates at the nasal bone fascia and upper cartilages. It inserts onto the skin at the medial lower forehead. Like the depressor supercilii, the procerus depresses the head of the brow. It is responsible for the horizontal rhytids at the radix of the nose. These muscles comprise the forehead musculature with which the surgeon must be thoroughly familiar for endoscopic dissection.

CLINICAL EVALUATION

The surgeon must recognize the fundamentals of forehead rejuvenation by understanding the changes that occur in the aging upper face. Forehead ptosis should be suspected in every patient who has redundant upper eyelid skin even if the eyebrow appears to be in a normal position. The patients invariably lift up the eyebrow with their finger when they want eyelid surgery (Flower's sign). This should be a cue to the surgeon to evaluate the patient for forehead, not eyelid, surgery. Also, upper eyelid skin hanging over the eyelid margin in the lateral periorbital area (Connell's sign) is a hallmark of forehead ptosis. The patients should be evaluated in repose to determine the situation accurately. Those with deep transverse forehead creases also suffer from forehead ptosis. Patients sometimes present with chronic forehead spasms, giving a falsely normal brow height. It is important to have the patient relax the forehead by gently closing the eye, which relaxes the frontalis muscle. This muscle is then blocked with the examiner's finger and the patient opens his or her eyes gently. The true level of the brow can then be measured accurately. The most common error is assuming that forehead ptosis is not present because the eyebrow appears normal. It is also important to note that women pluck their lateral brow to give the illusion that it is higher.

The goal of endoscopic forehead surgery is to elevate the brow, decrease forehead rhytids, decrease vertical glabellar rhytids, improve lateral canthal hooding, and decrease infrabrow skin. A proportional face should be divided into equal thirds, and a balanced face should be five eyewidths wide. Patients should be given a handheld mirror during the examination. This gives them the opportunity to look at themselves and specifically point to areas of concern. They can also describe their goals. Watch carefully for Flower's sign, and look for Connell's sign; this practice allows you to show them possible realistic surgical outcomes. Document this in writing and with photographs.

Two useful preoperative quantitative measurements are the glide test and the frame height. The glide test measures brow excursion in the medial, central, and lateral portions of the brow. The frame height measures the distance from midpupil to the top of the brow. Typically, the best improvements using the endoscopic forehead procedure occur with frame heights of 1.5–2.0 cm and glide test values of 2.0–3.0 cm. It is more common to undercorrect than overcorrect brow height. Most surgeons lift the brow 1.0–1.5 cm.

MEDICAL MANAGEMENT

Once the forehead evaluation is complete, the surgeon must develop a management plan. Recently, botulinum toxin has been used for eyebrow elevation. This is a temporary measure, lasting around 3–4 months. The uses of botulinum toxin are discussed in Chapter 9. It can be a useful tool to approximate the response of a permanent procedure, such as endoscopic foreheadplasty. It can also be used in conjunction with the endoscopic procedure.

SURGICAL MANAGEMENT

Most cases are performed under local anesthesia with sedation. When first starting this procedure, it may be wise to give general anesthesia in the event the patient becomes uncomfortable or moves. Lidocaine 1% with 1:100,000 epinephrine is used for the nerve blocks. Three branches of cranial nerve (CN) V₁ need to be specifically addressed. The supraorbital and supratrochlear nerves are blocked above the brow and medial brow, respectively. The superior lateral brow is innervated by the lacrimal branch of the trigeminal nerve and is therefore blocked at the tail of the brow. Attention is then given to the lateral orbital

rim. The zygomaticotemporal and zygomaticofacial nerves are branches of the V_2 distribution. They are infiltrated approximately 1 cm lateral to the lateral orbital rim and along the inferior rim laterally at the area of the malar bone. This block is especially useful if one is considering a mid-face lift. Sometimes it is useful to infiltrate the auriculotemporal nerve, which is a V_3 distribution. It emerges from the tragus anteriorly and courses cephalad. The rest of the infiltration is done along the surgical incisions and forehead above the periosteum using 0.25% lidocaine with 1:400,000 epinephrine. This is done up to 0.5 inch posterior to the hairline.

Marking is critical when planning for the surgery. There is a temporal crescent that separates the frontal pocket from the temporal pocket. This crescent is the fusion of the galea aponeurotica. It can be palpated along the lateral portion of the superior orbital rim, and it extends superolaterally. It is more pronounced when the patient clenches the jaw. The mark is continued along the posterior aspect of the lateral orbital rim to the superior border of the zygoma. If endoscopic mid-face surgery is desired, this marking can extend along the inferior orbital rim or the inferior border of the zygoma. The temporal branch of the facial nerve is a critical landmark. It runs from the lower portion of the tragus to 1.5 cm above the temporal eyebrow. It originates deep near the parotid gland and courses superiorly over the periosteum at the zygomatic arch. It then becomes more superficial and runs on the deep surface of the temporal parietal fascia before entering the undersurface of the frontalis muscle. A straight line is drawn from the lateral canthal angle to the midline between the ear and the temporal fusion line (temporal crescent). The area at the lateral canthus where the lines intersect is where the zygomaticotemporal (sentinel) vein courses. This should be the extent of a minimal lateral dissection for this procedure.

The supraorbital nerve can be measured approximately 2.4 cm from the midline, and the supratrochlear nerve is usually 1.6 cm from the midline. Sometimes branches of the supraorbital nerve are located more temporally and supply the surface of the skin. An arch extending 2–3 cm above the brow is marked to prevent injury to the supraorbital nerve. This nerve exits at the notch 60% of the time; the other 40% of the time it emerges from a foramen up to 1 cm above the brow. Blunt subperiosteal dissection can be done up to this point. A 1 cm safety zone is marked in the temporal area to prevent injury to the facial nerve. Blunt dissection can be performed temporally with reasonable safety up to this point.

One central, two paramedian, and two temporal incisions are made (Fig. 2-1). Sometimes two paracentral, two lateral, and two tem-

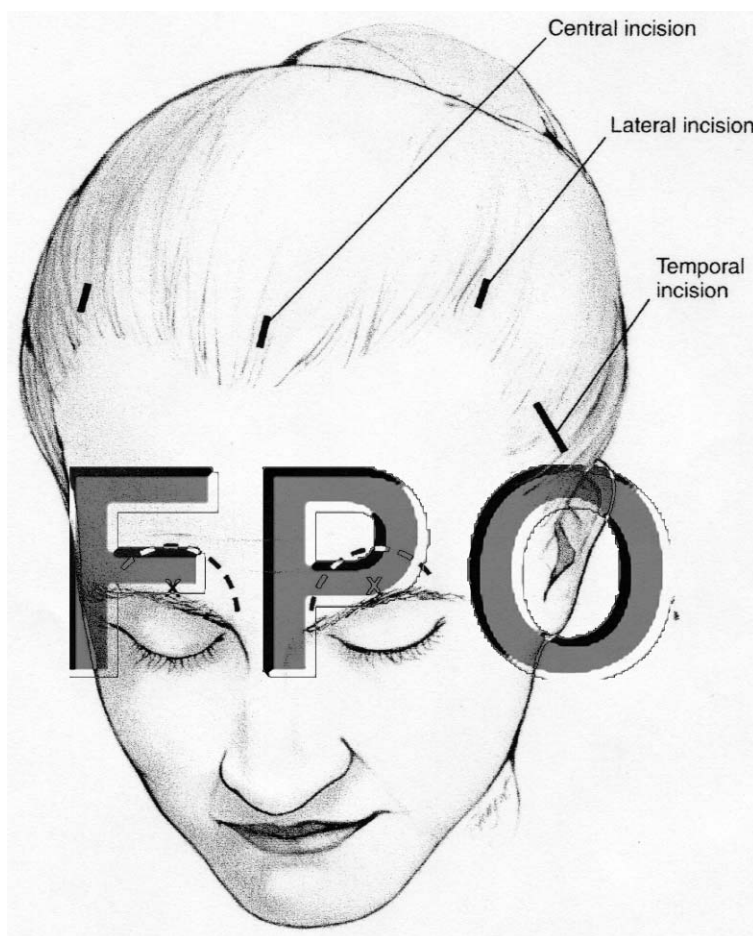


FIGURE 2-1. Incision sites for endoscopic foreheadplasty. The X marks the supraorbital notch, and the dotted line encloses an area where dissection is performed with direct visualization.

poral incisions are also needed. The central incision is marked at or 1 cm behind the hairline, extending 1.0–1.5 cm in length. The paramedian incisions are marked approximately 4.5 cm lateral to prevent injury to the superficial branches of the supraorbital nerve, which supply sensation between these areas. This incision extends 1.0–1.5 cm in length. The temporal markings are done 2.5 cm posterior to the hairline, extending 3.5 cm in length. The midline of this incision is perpendicular to a line drawn from the lateral nasal ala to the lateral canthal angle. In the presence of male pattern baldness, these incisions can be made behind the fringe line.

A No. 15 blade is used to make an incision down to the periosteum in the central incision. Blunt dissection in the paramedian incision is preferred to prevent bleeding from tributary vessels. The temporal incisions require more meticulous dissection. This incision is made through the dermis; with blunt dissection, then, spreading the tissue exposes the temporal parietal fascia, which moves with the skin. Further dissection exposes the deep temporalis fascia, which does not move and is superficial to the temporalis muscle. This fascia is a shiny, white, glistening tissue. The plane just above this white tissue at the superficial layer of the deep temporalis fascia is the plane of dissection (Fig. 2-2). The temporal branch of the facial nerve lies within the temporal parietal fascia and is superior to the surgical plane, out of harm's way. If desired, a 4 mm drill can be used for fixation at the posteriormost portions of the two paramedian or lateral incisions. This is done early in the procedure before the periosteum is released.

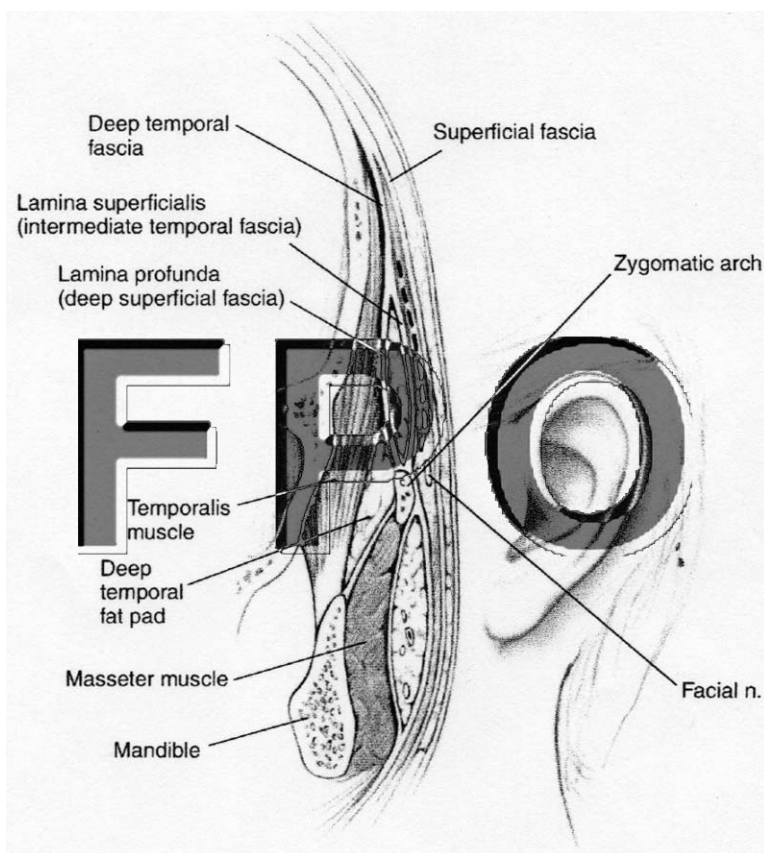


FIGURE 2-2. Anatomy in the temporal area. The dotted line is the appropriate plane of dissection.

The endoscope is now introduced through the temporal incision above the deep temporalis fascia. A blunt elevator is used in a direction toward the ear, remaining 1 cm posterior to the facial nerve marking, and the tissue is carefully elevated. The temporal and central pockets are connected blindly, laterally to medially, detaching the temporal crescent ligament, which is the fusion of the galea aponeurotica to the crest. Most surgeons prefer to dissect in the subperiosteal plane, especially if the forehead is high (Fig. 2-3). The subgaleal plane of dissection results in increasing the distance from the brow to the hairline. The dissection posteriorly is done behind the incision line. Some surgeons choose to extend this farther back toward the vertex. Continuing in the temporal pocket, dissection is carried out down toward the lateral canthal angle with direct endoscopic visualization. It is important to stay on the deep temporalis fascia while elevating upward gently. At this point the orbicularis-temporal ligament is identified, which is a tough ligament joining the lateral orbicularis to the deep temporalis fascia. Carefully dissecting beyond this point discloses the zygomaticotemporal (sentinal) vein. It is typically 5 mm temporal to the zygomaticofrontal suture line and is an important landmark. It is here that branches of the facial nerve are located, so the dissection should be minimal.

The lateral canthal ligament can be detached with endoscopic visualization. The arcus marginalis is then released along the supraorbital rim, extending medially toward the supraorbital nerve by incising the periosteum. Once the supraorbital nerve is located, a suprapariosteal pocket is formed above the bridge of the nose to address the depressor muscles (procerus, corrugator, depressor supercilii, orbicularis). Using blunt dissection, the tissues are moved side to side to separate the muscles for better visualization. At this point the tough corrugators can be seen with their insertion and origin on both sides. The corrugators can be avulsed, rather than cut, to prevent injury to the supratrochlear nerve. This can be accomplished with endoscopic scissors or laser. Branches of the supratrochlear nerve are sometimes seen within the corrugator and should be avoided. The procerus can be addressed in a similar fashion, with avulsion. The depressor supercilii should also be avulsed and not cut because of vessels within it. The orbicularis muscle can be visualized within this area and can be cut vertically. To eliminate the glabellar lines, vertical incisions can be made in the periosteum centrally, up to the dermis. At this point, some surgeons choose to perform multiple vertical interfascicular neurotomies to the superficial branches of

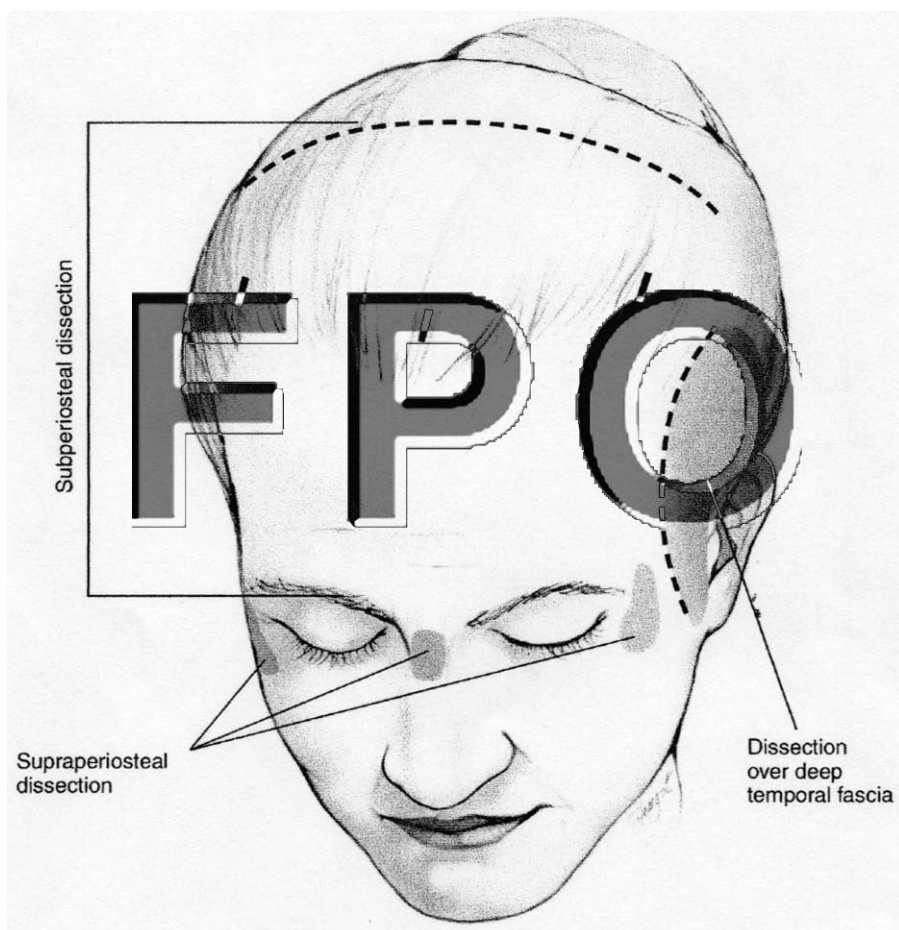


FIGURE 2-3. Areas of subperiosteal and suprapariosteal dissection.

the facial nerve along the superior brow lateral to the supraorbital nerve. This practice theoretically prevents regeneration of the depressor muscles after the surgery, thereby decreasing the chance of recurrent postoperative brow ptosis.

FIXATION

Once the periosteum has been adequately released, attention is given to fixation. There are many methods available to fixate the scalp. The key to the endoscopic forehead procedure is not as much the fixation

as it is the release of the periosteum and the muscles. Anchor or screw techniques for fixation include use of an internal screw or plate, Mitek anchor, external screw, and k-wire. Other techniques include galea-frontalis-occipitalis release, use of lateral suspension sutures or bolster fixation sutures, anterior scalp port excision, galea-frontalis advancement, creation of a cortical tunnel, and use of tissue adhesives. Regardless of the technique, it must achieve simplicity, reproducibility, safety, and long-term results. If the fixation is under tension, brow ptosis occurs. We prefer the Mitek anchor screw or the cortical bone tunnel technique for fixation.

With the Mitek screw, a 4 mm drill bit is used in the outer calvarium approximately 1.0–1.5 cm from the anteriormost portions of the lateral or paramedian incisions. Once drilled, a 2-0 suture and needle attached to the screw is passed from anterior to posterior through galea-periosteum at the anterior portion of the lateral or paramedian incision. This is a double-armed suture; therefore both are passed anteriorly, elevating the scalp once secured (Fig 2-4). The temporal region is closed with 3-0 or 4-0 nylon suture from the temporal parietal fascia to the deep temporalis fascia. The remainder of the skin is closed with surgical staples.

When using the cortical bone tunnel, the instrument is placed in the lateral or paramedian incision. Sometimes it is necessary to enlarge the incision to accommodate the instrument. A 4 mm drill bit is used to drill on each side of the instrument, which allows two 45-degree holes that meet in the outer calvarium. A 3-0 or 4-0 nylon or Ethibond suture is pulled through the hole with a hook and sutured in the fashion described earlier.




FIGURE 2-4. Fixation using the Mitek anchor.

POSTOPERATIVE CARE

After the hair is washed with shampoo, ABD pads and Kerlex dressings are placed around the forehead for 48 hours. Complete wound healing usually occurs within 42–60 days. Postoperative antibiotics are not routinely prescribed. A prednisone taper is given, and the patient is seen in 2 days to remove the dressing. The staples are removed within 7–10 days. Patients usually can return to work within 3–5 days. They are instructed preoperatively that scalp numbness may persist for 3 months, and “hair shock” can result in some alopecia around the incision sites also lasting 3 months.

A worrisome complication is injury to the facial nerve, but it can usually be avoided by carefully dissecting in the correct plane. Hematomas and infections are rare. This procedure can be performed on bald patients with minimal scarring. Endoscopic foreheadplasty is an accurate procedure that has a higher patient acceptance rate than the traditional coronal lift. It is a nice addition to the surgeon’s armamentarium of browlift procedures.

DIRECT EYEBROW LIFT

- César A. Sierra, MD

*Department of Ophthalmology
Yale University School of Medicine
New Haven, Connecticut*

Before moving to more complex approaches such as the endoscopic eyebrow lift, the surgeon must master the fundamental concepts of preoperative evaluation, indications for surgery, surgical anatomy, and the basic direct browlift procedure.

The direct eyebrow lift is generally performed with local anesthesia and requires excising the tissues adjacent to the superior line of the brow follicles. The advantages of a direct approach include less operating time, less anesthesia, and the ability to address the whole eyebrow or a specific segment of it by manipulating the shape of the excised tissue. In general, the closer the surgery is performed to the eyebrow the more effective it is. The direct browplasty is therefore an excellent option in cases of severe brow ptosis or in patients with a receding hairline or baldness where incisions used for other approaches would leave noticeable scars. The degree of elevation and the long-term results are excellent when compared with other approaches. The major negative aspect is the inferior cosmetic outcome with a supraciliary scar that is sometimes more visible than expected, depending on the healing ability of the patient.

ETIOLOGY

As the aging process continues, the gravitational syndrome occurs at different rates in different people, resulting in sagging or involutional ptosis of the eyebrow with redundancy of skin. Downward displacement of the tissues also takes place as a result of facial overactivity patterns such as squinting and frowning. In these cases the overactive depressor muscles determine the most affected area of the brow. Paralysis of the facial nerve [cranial nerve (CN) VII] or its temporal branch also leads to moderate to severe eyebrow ptosis with blunting of the ipsilateral forehead rhytids due to loss of tone of the frontalis muscle.

PREOPERATIVE EVALUATION AND INCISION MARKINGS

The position of the eyebrows is extremely important when evaluating a patient who complains of superior visual blockage or drooping eyelids. Commonly, patients who present with upper eyelid ptosis or dermatochalasis also have eyebrow ptosis. This sagging of the eyebrow can add fullness and weight that, when combined with an abnormal levator muscle or excessive eyelid skin, can result in more hooding and loss of superior visual field. Recognition is crucial to prevent inadequate surgical management and failure to help the patient.

Gender differences exist, with eyebrows being higher, more arched, and slightly raised laterally in women. Male eyebrows are usually described as T-shaped: They are less inclined and lower, with the inferior border at the level of the superior orbital rim. This baseline difference could be the reason that brow ptosis is more prevalent in men than in women.

The preoperative evaluation is always performed with the patient sitting upright with relaxed frontalis muscle action. A 1:1 lift desired/skin excised ratio is used. The eyebrow is manually elevated to an appropriate position. This amount of lift is measured using a ruler in the lateral, central, and medial aspects of the eyebrow. A fusiform skin incision pattern is usually obtained where the upper line of eyebrow hair follicles dictates the inferior marking, and the superior marking is given by the measurements previously taken for each portion of the eyebrow. As a general rule, the inferior incision line should include a small number of the superiormost brow hairs

to conceal the scar. It is also recommended that the supraorbital notch be marked to maintain awareness of where the supraorbital neurovascular bundle exits and becomes more superficial.

SURGICAL MANAGEMENT

After the skin markings are outlined with a surgical marking pen, the area is adequately infiltrated with local anesthetic. The incision (Fig. 3-1) is started at the inferior marking where the superiormost brow follicles follow a cephalad orientation. The incision must be made with the blade beveled parallel to these follicles to prevent ex-

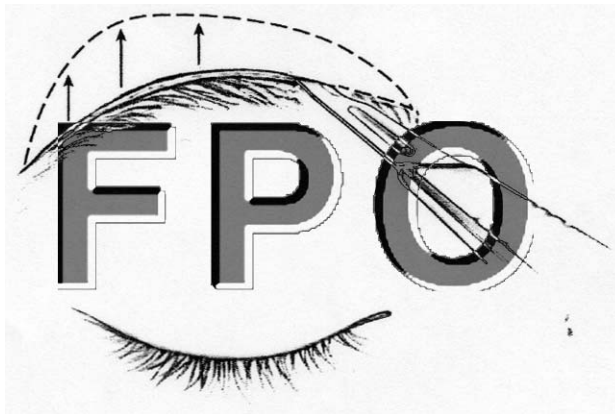


FIGURE 3-1. Suprabrow incision after marking the incision site.

cessive damage, loss of eyebrow hair, and a conspicuous scar (Fig. 3-2). The incision on the superior marking follows, with the blade angled in the same direction to provide adequate apposition and eversion of the wound edges. Care should be taken at all times to incise superficially in the area of the supraorbital neurovascular bundle to avoid inadvertent injury. Deeper sharp dissection and excision of the skin and subcutaneous tissue are done laterally, where there is no risk of damage to the supraorbital neurovascular bundle (Fig. 3-3). Careful superficial dissection in the medial aspect of the eyebrow and hemostasis follows.

The wound is first reapproximated with buried subcutaneous 5-0 Vicryl. Each suture must be perfectly aligned in the plane horizontal to the wound edges. It is also crucial that the bites taken with this suture maintain exactly the same depth in the vertical aspect of both sides of the wound to provide precise apposition of the edges, thereby decreasing scar formation.

The tendency of the scar as it heals is to draw the skin toward the vertical axis, depressing it. Therefore the epidermis should be closed with a 6-0 nonabsorbable suture in a vertical or horizontal mattress fashion to achieve an adequate amount of eversion of the skin edges to allow the expected flattening.

For cases of severe facial nerve (CN VII) paralysis, it is recommended that dissection be carried deeper through the frontalis muscle and nonabsorbable 5-0 or absorbable 4-0 sutures be carefully passed through the muscle and periosteum in a buried fashion to achieve better fixation of the ptotic brow. For milder cases of brow ptosis, this technique would create a more depressed scar and diminish the action of the frontalis muscle. The asymmetry created by unilateral blunting of the deep forehead rhytides in these cases can be corrected if the incision is created in the mid forehead instead of the superior edge of the eyebrow.

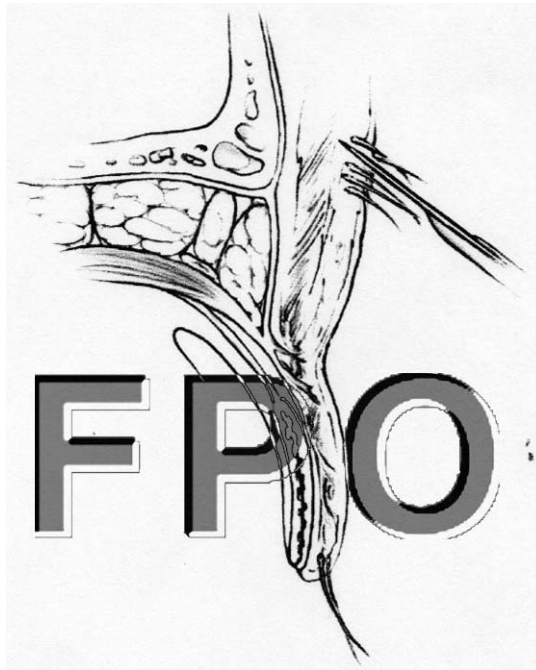
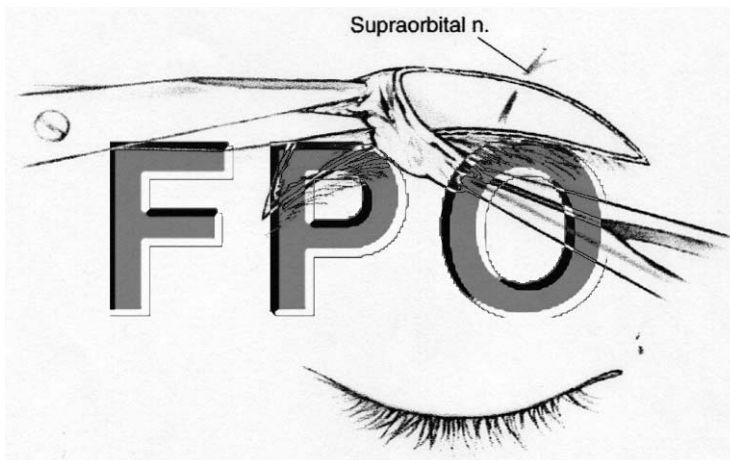


FIGURE 3-2. Incision is beveled away from the brow hairs to parallel the direction of the follicles.

FIGURE 3-3. Skin and muscle flap are removed with scissors. In the region of the supraorbital nerve, the dissection must be superficial to avoid damaging the nerve.



POSTOPERATIVE CARE

Ophthalmic antibiotic ointment or a combination of antibiotic and steroid is applied at the end of the case. Bandaging is generally not necessary. The patient is instructed to use ice packs 15 minutes each hour while awake for the next 2–3 days and to elevate the head with several pillows at bedtime. Straining, lifting heavy objects, and bending should be avoided for 1 week. The sutures can be removed as soon as 7 days after surgery to avoid epithelialization of the suture tracks. Surgical adhesive strips may be used at this time if needed. To minimize the evidence of a scar the patient is instructed to reduce sun exposure to the area by wearing a hat or applying lotions with a sun-protection factor of 45 or more.

RHYTIDECTOMY SURGERY

A variety of methods exist for facelift surgery (rhytidectomy). The more complicated techniques involve extensive undermining of the superficial musculoaponeurotic system (SMAS) or subperiosteal dissection. The simpler techniques employ plication or imbrication of the SMAS. Several of these techniques are presented here so the surgeon can choose the technique with which he or she is most comfortable and that most benefits the patient.

CLINICAL EVALUATION

The initial patient evaluation is of paramount importance. It is critical to understand the patient's concerns. Unrealistic desires on the part of patients can only lead to surgery that fails to please them. Have patients hold a mirror and show you all the areas of their face they would like to see improved. If they do not specifically point to important areas ask them about their chin and neck, jowls, nasojugal fold, and nasolabial fold. Make note of the quality of the skin, the amount of redundant tissue, the presence or absence of platysmal bands and the amount of submental fat. If significant platysmal bands or deep nasolabial folds are present, they should be discussed preoperatively with the patient as they are difficult to correct fully.

Evaluation of the chin and neck directly affects the surgery performed in this area. If minimal submental fat and skin laxity are present, submental liposuction is performed and the skin dissection in the neck does not extend into the central neck and submental area. Conversely, if significant submental fat, platysmal bands, or skin lax-

ity is present, the dissection extends further into the neck (Fig. 4-1). Direct lipectomy is performed through a submental incision, and platysmal plication may be necessary.

In addition to evaluating surgically important facial features, it is important to discuss smoking and medication usage with the patient. Smoking during the perioperative period can lead to flap necrosis secondary to vasoconstriction. It is imperative that the patient not smoke for 2 weeks before and 2 weeks after surgery. Any medications that inhibit platelets or coagulation must be stopped an appropriate time prior to surgery. These include but are not limited to aspirin, many other nonsteroidal antiinflammatory drugs, warfarin (Coumadin), and clopidogrel (Plavix). These medications can increase the possibility of the patient developing a hematoma underneath the facelift flaps, which can lead to flap necrosis.

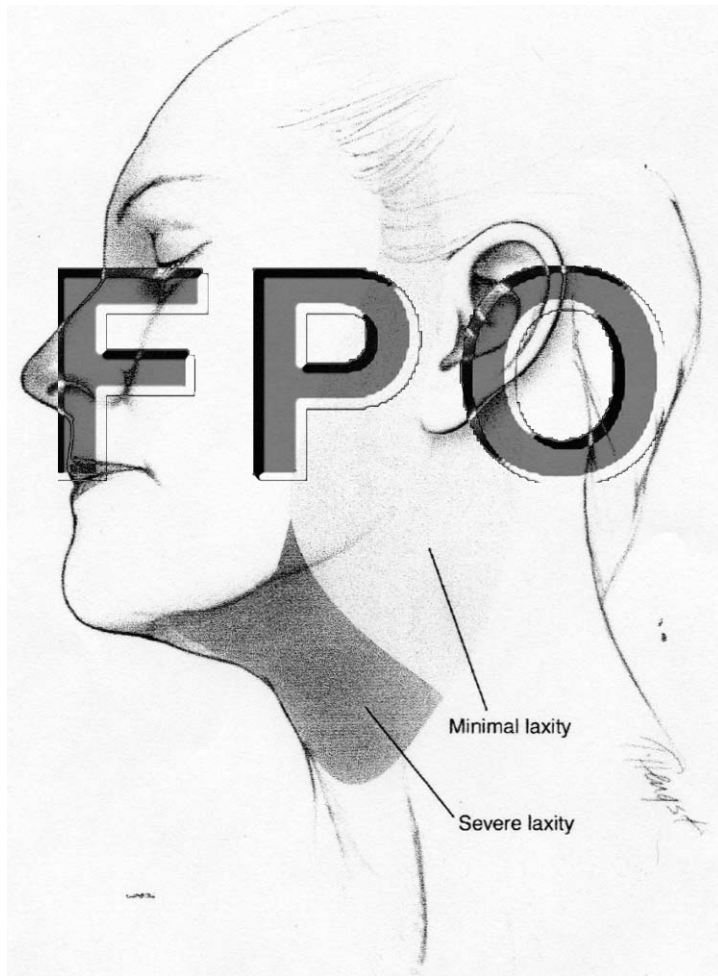


FIGURE 4-1. Extent of subcutaneous skin dissection for minimal and severe laxity of neck skin.

SURGICAL MANAGEMENT

At the beginning of the procedure the facelift incision is marked in front of the ear with a fine-tipped marker (Fig. 4-2). A heavier marker is more appropriate in the temporal hairline and the retroauricular area. Marking should be performed prior to administering the local anesthetic. If platysmal bands, which represent the medial border of the platysmal muscle, are present, they should be marked to facilitate finding the medial borders during the plication procedure. If significant submental fat is present, the lateral extent of this compartment should be marked to guide submental liposuction or direct lipectomy.

The temporal incision is directed superiorly and temporally for several centimeters. It parallels the temporal hairline and is placed several centimeters posterior to it. The incision begins at the anterior helix and extends superiorly and anteriorly. We typically utilize a pretragal incision, which follows the anterior helix and the tragus. This incision conforms to the natural contours of the ear and helps avoid a straight-line scar, which tends to be more noticeable and cosmetically objectionable. Many surgeons utilize a posttragal incision, which must be used with care. If not performed carefully, the tragus can be pulled forward during the healing process, causing an unnaturally open ear.

The incision continues under the lobule of the ear. In the area of the lobule, a 1- to 2-mm rim of skin is left attached to the lobule. This helps keep the lobule anchored in its normal position. If this rim of tissue is too wide, it is noticeable postoperatively. The incision continues superiorly to the level of the external auditory canal several millimeters onto the conchal cartilage. During the postoperative period the incision migrates posteriorly into the fold. (If the incision is initially placed in the fold, it migrates onto the mastoid area and is visible.) The incision turns posteriorly and continues for several centimeters into the occipital hairline. If a large skin excision is anticipated or the patient wears his or her hair quite short the incision can be placed just anterior to the hair line. This prevents an unnatural “step” in the hairline after skin excision.

An additional incision is placed in the submental area, permitting submental liposuction, direct lipectomy, or modification of platysma bands. The incision should be placed several millimeters posterior to the naturally occurring submental crease. (An incision placed directly on the crease can result in deepening of the crease, which is cosmetically objectionable.)

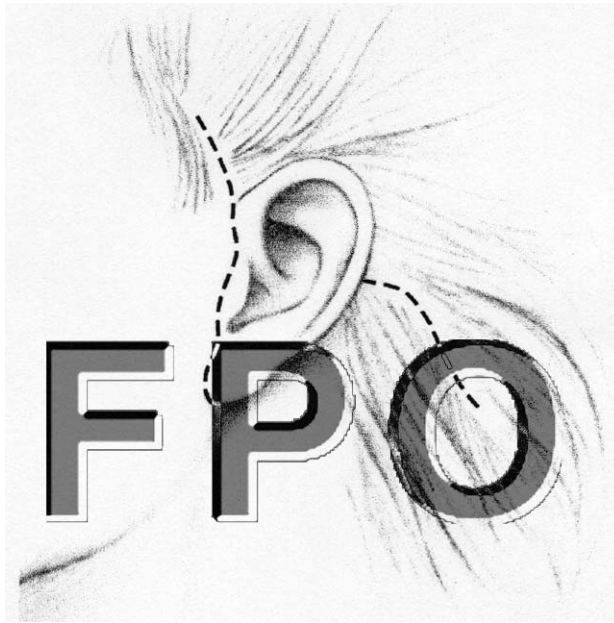


FIGURE 4-2. Typical incision for rhytidectomy.

Various facelifting techniques require different degrees of skin undermining. For SMAS plication or imbrication techniques a relatively large skin flap (6–8 cm) is prepared in the preauricular area. For techniques that develop a large SMAS flap, less skin undermining is performed. In these cases a skin flap of 3 cm is typically raised.

Intravenous sedation or general anesthesia can be utilized depending on the preference of the surgeon and the health and wishes of the patient. An equal mixture of 1% lidocaine with epinephrine and 0.75% bupivacaine is injected along all incision lines. A small incision is made in the pre- and postauricular areas and in the submental area to allow introduction of a small cannula. Tumescant solution is infiltrated through these incisions in a subcutaneous plane in all areas to be undermined. A simple tumescant solution consisting of 1000 cc normal saline and 50 cc 2% lidocaine is employed. Hemostasis is improved and anesthesia provided.

When direct lipectomy is planned or platysmal bands need to be modified, a 2.5 cm incision is marked just posterior to the submental crease. If submental liposuction is planned, a much smaller (3 mm) incision is marked to allow introduction of a 3 mm liposuction cannula. This incision must be kept small to prevent loss of suction during the liposuction portion of the procedure.

Submental liposuction should be limited to the area bordered by the mandible. The marginal mandibular nerve is superficial in the area of the angle of the mandible, and liposuction should be avoided in this region. If the submental fat has been properly marked preoperatively, liposuction need not extend outside this area.

When significant submental fat is present, direct lipectomy is indicated. The 2.5 cm incision allows direct visualization of the fat and eventually the edges of the platysmal muscle. A subcutaneous dissection is performed with facelift scissors in the previously marked submental area. Approximately 5 mm of subcutaneous fat is left attached to the skin flap, which helps prevent unusual adherence of the skin to the underlying tissue during healing. A small (0.5 inch) lighted retractor aids in visualization and obtaining hemostasis. Preplatysmal fat is removed with the scissors. The edges of the platysma muscle can be visualized and plicated if significant platysmal bands are present (Fig. 4-3). Marking the bands on the skin surface preoperatively helps locate the medial edges of the muscle during dissection. The medial edges of the platysma are plicated with multiple 4-0 permanent sutures. The skin in this area is closed with a running 6-0 nylon suture. No skin excision is performed.

Once neck repair is complete, the facial incision can be performed. This incision is made with a Bard-Parker No. 15 blade and is kept parallel with the hair follicles to avoid hair loss. In the temporal area the dissection can be performed using the back of a blade handle. The handle is pushed firmly in a plane just under the skin. Blunt dissection avoids damaging the hair follicles, and it stays superficial to the frontal branch of the facial nerve. The facial nerve is quite superficial in this area, running within the superficial temporalis fascia. This subcutaneous dissection terminates halfway between the ear and the lateral canthus.

Anterior to the ear the skin is tightly adherent to the underlying tissue, making dissection difficult for the first several centimeters. A No. 15 blade is useful for this initial portion of the dissection. A facelift scissors is then used to complete an extremely superficial dissection. Countertraction with a double skin hook simplifies the dissection and leaves the underlying SMAS intact. Depending on the SMAS technique employed, this dissection creates a skin flap 3–8 cm in length.

The retroauricular portion of the incision is often started with the No. 15 blade as well. The skin overlying the mastoid process is adherent to the underlying tissue. Once the dissection becomes easier, a facelift scissors can be employed. As the dissection proceeds inferiorly in the neck, it is important to maintain a superficial dissection plane between the subcutaneous tissue and the superficial musculature. The great auricular nerve becomes extremely superficial as it crosses the body of the

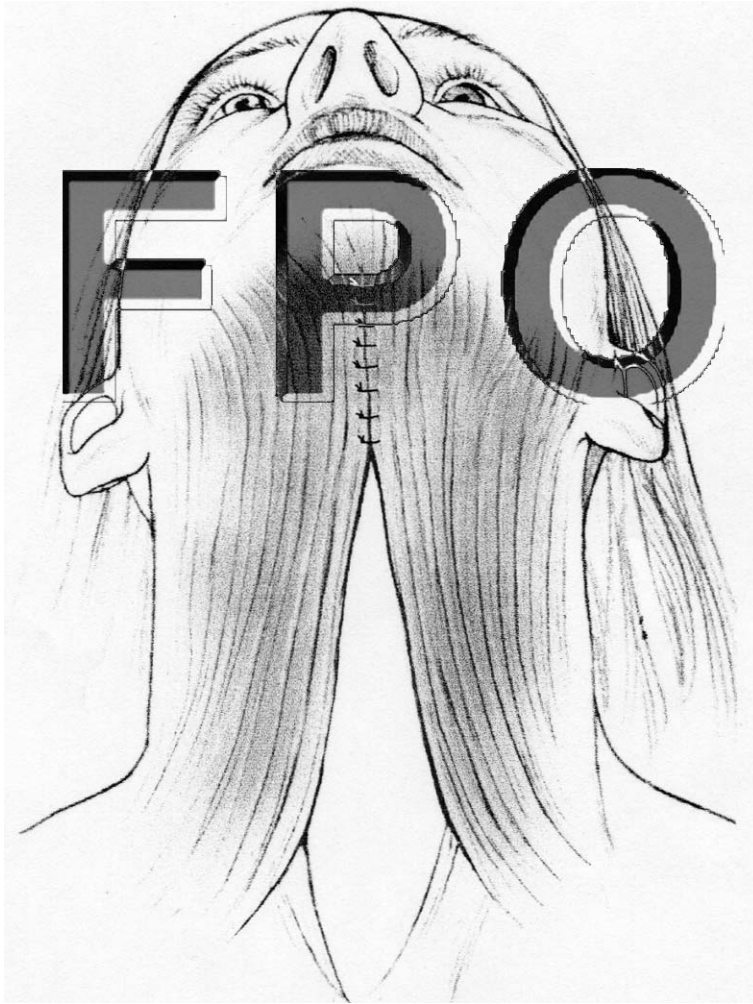


FIGURE 4-3. Platysma muscle plicated in the midline to reduce banding in the neck.

sternocleidomastoid muscle 6.5 cm below the external auditory canal. Deep dissection in this area can sever the great auricular nerve.

Once the flaps have been raised and again prior to skin closure meticulous hemostasis should be ensured. A wide (1.5 inch) lighted retractor is invaluable for performing this task.

Various techniques can be used to treat the SMAS. The goal of SMAS modification is to provide deep support and tightening for the areas of the jowls, nasojugal fold, nasolabial fold, and neck. SMAS modification can impart longevity to the procedure and allows less

tension to be applied directly to the skin, producing a more natural appearance postoperatively. The techniques for SMAS plication, SMAS imbrication, and deep SMAS dissection are presented.

SMAS Plication

SMAS plication is the simplest of the three techniques. Here, the SMAS is sutured to itself in several locations without excising any tissue. The platysma and the SMAS are easily seen after the skin flaps are elevated. The SMAS has the appearance of muscle tissue interspersed with lumpy fat deposits. This complex is mobile and can be moved as a single unit. When the SMAS is grasped near the anterior mandibular ramus and the platysma is grasped in the neck, the entire complex can be repositioned in a posterolateral direction. The cheek and neck skin are observed to move in a similar direction, tightening the neck, jowls, nasojugal fold, and nasolabial fold. A 4-0 nonabsorbable suture is used for the plication.

Three primary areas of the SMAS are tightened (Fig. 4-4). The first and most superior suture tightens the nasolabial fold. The direction of repositioning should be mostly posterior and slightly superior, perpendicular to the nasolabial fold. The next suture repositions the jowls and nasojugal fold. This suture should exert a pull that is mostly superior and slightly posterior. The final suture helps elevate the neck. This suture, which should be directed superiorly and slightly posteriorly, grasps the platysma below the ear and attaches it the fascia overlying the mastoid process. Several interrupted or mattress sutures are used in each location.

SMAS Imbrication

The technique for SMAS imbrication is similar to that for SMAS plication. Instead of folding the SMAS on itself, however, an ellipse of SMAS is excised, and the edges are sutured together. A relatively safe area for SMAS excision lies between the zygomatic arch and the angle of the mandible. The facial nerve is deep to the SMAS in this area. Excision above the zygomatic arch would risk severing the frontal branch of the facial nerve. The marginal mandibular nerve is at risk if the excision extends over the angle of the mandible.

The SMAS excision starts just below the zygomatic arch and 1.5 cm anterior to the tragus. The excision extends inferiorly toward the angle of the mandible: the greater the tissue laxity, the wider the excision should be. When the edges are sutured together, the degree of tis-

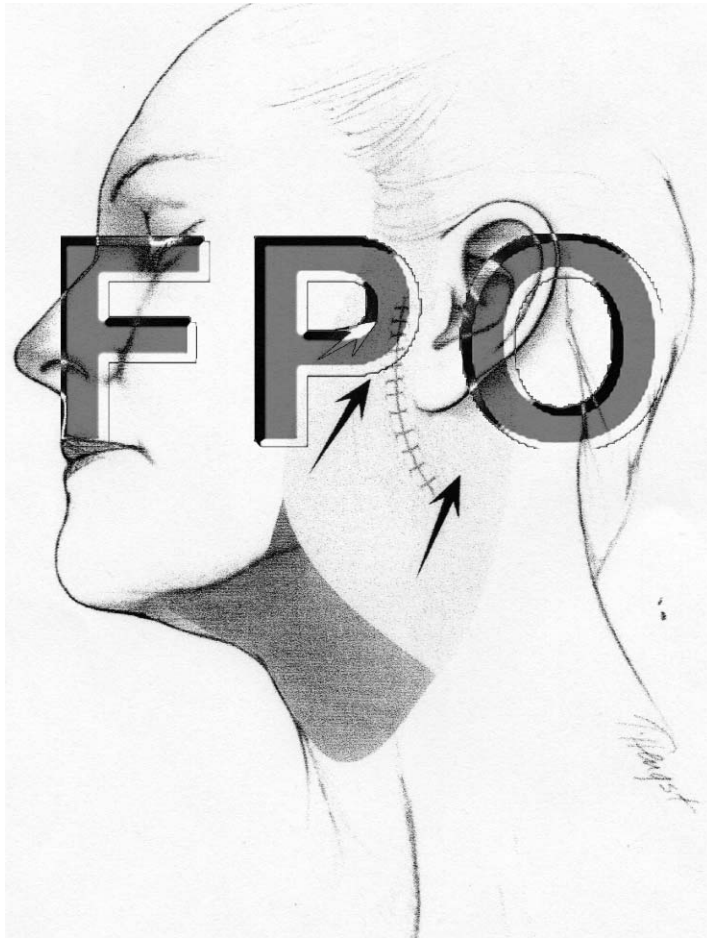


FIGURE 4-4. Typical superficial musculoaponeurotic system (SMAS) incision and direction of the SMAS elevation.

sue repositioning is observed. If repositioning of the jowls, nasojugal fold, and cheek tissue is inadequate, wider excision can be performed and the area resutured. Sutures are placed in the same areas as with the SMAS plication technique. As for SMAS plication, a final suture grasps the platysma below the ear and elevates it superiorly and slightly posteriorly, attaching it to the fascia overlying the mastoid process.

Deep SMAS Dissection

Another technique is deep SMAS dissection. Here, a shorter skin flap is created followed by dissection of an SMAS flap. A safe area

for SMAS dissection is between the inferior border of the zygoma and the angle of the mandible. The SMAS dissection in this area is begun with facelift scissors. Blunt dissection with the scissors parallel to the plane of the SMAS continues the plane medially to the area of the malar eminence. Redundant SMAS is excised, elevated, and sutured as with the previous techniques. The platysma is plicated to the mastoid process. Because a smaller skin flap is created, this technique is more dependent on SMAS repositioning for its result. Deep SMAS dissection is more appropriate for patients with prominent jowls and nasojugal folds. SMAS plication or imbrication, because they involve a larger skin flap, are more effective when the patient exhibits extensive deep rhytides and frankly redundant skin.

Once the SMAS is repositioned, the skin can be redraped and trimmed. Because deep support has been provided by the SMAS repositioning, the skin can be redraped in a natural appearing posterior and slightly superior direction. This ability to reposition the SMAS and the skin in different directions is a major advantage of the various techniques that utilize the SMAS for deep support. Excess skin is most noticeable in the occipital hairline area and anterior to the ear.

Prior to skin excision two cardinal staples are placed. These staples, which provide support for the skin flaps, can be under moderate tension. To minimize scarring, the rest of the incision should be closed with minimal tension. The first cardinal staple is placed at the anterosuperior border of the ear, where the ear meets the scalp. The flap is advanced in various directions until the desired effect is achieved. When the ideal angle is determined, the point of overlap is marked. A linear incision is made to the point of overlap, and the flap is secured to the fixation point with a single staple.

The second cardinal staple is positioned at the most anterior portion of the occipital incision in the retroauricular sulcus. The skin of the neck is elevated posteriorly and superiorly to reduce the rhytides in the neck, and the staple is then placed under moderate tension. After subcutaneous sutures are placed to close the remainder of the occipital wound, the posterior staple is not under significant tension. Extreme tension is not necessary because a significant portion of the beneficial effects in the neck are produced by the platysmal plication and liposuction.

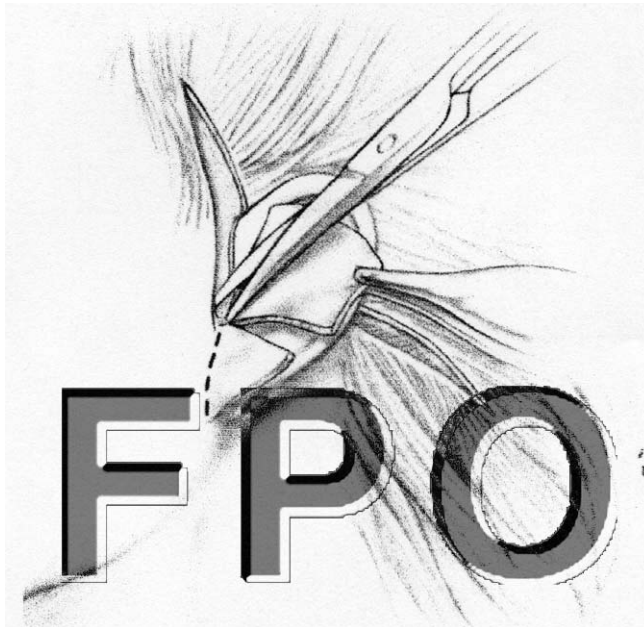
The skin must be trimmed and closed carefully and meticulously. In the preauricular area it is critical that the incision be closed without tension to minimize scarring in a potentially visible area. Additionally, excessive skin removal in this area can pull the tragus forward, opening the ear and producing an unnatural postsurgical

appearance. The skin is trimmed precisely so the wound edges just appose (Fig. 4-5), and a running 6-0 nylon suture is utilized to close this portion of the incision.

Only a small amount of skin is typically excised in the temporal area. The purpose of this portion of the incision is to avoid producing a “dog ear” when closing the cheek flap. Scissors are utilized to excise the skin, and this portion of the incision is closed with staples.

In contrast, in the occipital area a large amount of skin is usually excised along the posterior portion of the flap. This excision is important in that it allows appropriate flap rotation and tightening of the skin of the neck. This area can tolerate moderate tension. Care is taken to avoid forming a “dog ear” when trimming and suturing this area. Absorbable sutures (4-0) such as Vicryl are placed subcutaneously. These sutures minimize tension in this area and therefore decrease the chance of hypertrophic healing. Final closure of the posterior occipital flap is performed with staples. Closure from the posterior to anterior direction minimizes the chance of developing a “dog ear” deformity. The anterior (postauricular) portion of this flap usually requires little trimming. A 6-0 nylon running suture is placed in this area.

FIGURE 4-5. Trimming the preauricular skin.



The ear lobe sits approximately 12–15 degrees posterior to the long axis of the ear. Excessive skin removal in the area of the ear lobe can displace it anteriorly or inferiorly. If desired, the ear lobe may be secured in position with a single interrupted 6-0 Vicryl suture. This suture subcutaneously attaches the most inferomedial portion of the ear lobe to the underlying SMAS tissue.

POSTOPERATIVE CARE

The use of drains is controversial. If desired, a Jackson-Pratt drain can be placed through a small stab incision in the occipital portion of the flap and passed into the neck. The drain can be gently secured to the occipital scalp with a 4-0 nylon suture. Approximately 50% of surgeons utilize drains. When used, the drains are usually removed on the first postoperative day.

A bulky dressing is applied. ABD pads are placed over the pre- and postauricular areas. A Kerlex dressing is rolled over the head, ears, and neck, holding the ABD pads in place. This dressing should not be so tight as to cause pain or place pressure on the flaps. Excessive pressure can lead to flap necrosis. The dressing is removed in 24 hours. Sutures are removed in 1 week and staples at 7–10 days.

MID-FACE LIFT

- Robert Alan Goldberg MD

*David Geffen School Medicine at UCLA;
Orbital and Ophthalmic Plastic Surgery
Jules Stein Eye Institute,
Los Angeles, California*

Deflation and descent of the mid face is a central feature of facial aging. To address these changes, the surgeon has to consider both volume augmentation and vertical repositioning.

VOLUME AUGMENTATION

Volume augmentation (e.g., using free fat injections, orbital fat on vascular pedicles in conjunction with blepharoplasty, or tear trough or submalar implants) is an important part of mid-face rejuvenation. Volume augmentation is beyond the scope of this chapter.

VERTICAL REPOSITIONING

Vertical elevation of the mid-face tissues can be accomplished along various vectors and through various incisions. Potential planes include the preperiosteal suborbicularis oculi fat (SOOF) plane and the subperiosteal plane. Potential vectors include the vertical, supero-

lateral, and lateral vectors. Potential incisions include transoral, transconjunctival, canthal, eyelid crease, and temporal hairline incisions (Fig 5-1). Fixation options include orbital rim, malar hang-back, and temporoparietal fixation. For aesthetic mid-face rejuvenation, the appropriate vector is superior or superolateral. The incisions must be cosmetically acceptable, and I believe the temporal incision is optimal, although the suprabrow incision heals acceptably well in some patients and may be the best option for a man with a receding hairline. In my opinion, canthal and eyelid crease incisions are unacceptable for an aesthetic mid-face lift.

Through either the temporal or suprabrow incision, I prefer elevating the mid-face in the subperiosteal plane. This plane is safely deep to the facial nerve, easily dissected, and relatively blood free. It creates a periosteal pennant that heals back down to the zygoma in an elevated position, providing stable, broad-based fixation for long-term successful elevation of the mid-face.

The mid-face lift performed in the subperiosteal plane elevates the entire cheek as a composite flap. It does not address loss of skin elasticity, loss of subcutaneous fat, or cutaneous ptosis. It is my belief that no surgery can accomplish long-term lift of the superficial tissues; hence, skin flaps are short-lived in their effect. A cable lift^{1,2} is a reasonable alternative to a cutaneous flap for elevating the more superficial tissues and jowls and can be combined with a subperiosteal temporal lift.

Both the temporal approach and the suprabrow approach have the added benefit of elevating the temporal eyebrow and lateral eyebrow fat pad. If the deep head of the lateral canthal tendon at its attachment to the orbital rim is left intact, there is minimal long-term elevation of the canthal angle. If the surgeon does wish to elevate the lateral canthal angle (e.g., if there is congenital or iatrogenic canthal dystopia) release of the deep head of the canthal tendon and associated canthal retinaculum allows the canthal angle to rise with the flap.




FIGURE 5-1. Incisions and vectors.

SURGICAL TECHNIQUE

Surgery is performed under monitored local anesthesia with sedation. Nerve blocks of the supraorbital, orbitozygomatic, and infraorbital nerves are accomplished with 2% lidocaine with epinephrine. Then tumescent anesthesia of the upper and mid-face is achieved using 200–300 cc of dilute lidocaine with epinephrine solution (0.1% lidocaine with 1:1,000,000 epinephrine).

The temporal incision is designed so the mid-face can be elevated along the vector from the angle of the mouth through the angle of the canthus. The temporal incision is designed to lay over the deep temporal fascia, so the fascia can be accessed for fixation of the flap (Fig. 5-1).

Initially, under direct elevation by lifting the flap with an angled retractor and then under endoscopic visualization after the plane has been started, dissection is carried out between the shiny, gray, deep temporal fascia and the overlying gauzy superficial temporoparietal fascia. The facial nerve lies in the superficial temporoparietal fascia, so care must be taken to maintain an accurate plane on the deep fascia, thereby avoiding injury to the facial nerve (Fig. 5-2).

On the medial edge of the deep temporal fascia, the frontal periosteum and deep temporalis fascia join together along the temporal line; this area is referred to as the conjoined tendon. The conjoined tendon is dissected sharply, providing visualization of the frontal bone in the subperiosteal plane on the medial edge of the deep temporal fascia. The conjoined fascia is followed along the temporal line to the junction of the zygoma, at the same time dissecting the subperiosteal plane over the frontal bone medially and the deep plane between the superficial fascia and the deep temporalis fascia laterally. As the superior orbital rim is approached, the deep temporalis fascia splits into two layers, separated by the intermediate temporal (Yasergil's) fat pad. Once Yasergil's fat pad is identified, the appropriate plane of dissection is on its surface, which is the undersurface of the superficial layer of the deep temporal fascia. This plane is followed down to the takeoff of the zygomatic arch, which can be palpated with the dissector before it is actually visualized.

Typically, a large vein emerges from Yasergil's fat pad approximately 2 cm lateral to the orbital rim and at about the level of the superior orbital rim; this sentinel vein should be sought and presumptively cauterized with bipolar cautery. The dissection is continued subperiosteally over the zygoma along the lateral orbital rim. The arcus marginalis is recognized as a tight attachment at the orbital rim itself, which can be identified by the slope of the zygoma as it curves into the orbit. As the subperiosteal plane is taken down toward the inferior orbital rim and over the wider portion of the zygoma adjacent to the arch takeoff, the surgeon typically encounters the temporozygomatic neurovascular bundle; if possible, this is left hanging across the dissection plane, although sometimes it is impossible to avoid cutting this branch. Symptomatic numbness is almost never produced, however, even if this nerve is cut.

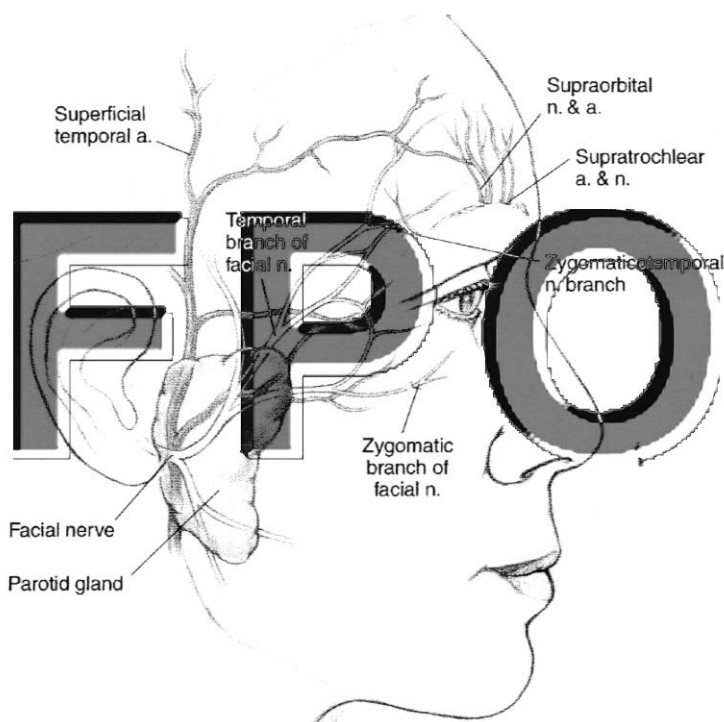


FIGURE 5-2. Anatomy of the temporoparietal fascia, facial nerve, and deep fascia.

After the zygomatic arch takeoff is recognized, a dissection plane is carefully created in the subperiosteal plane over the arch. The frontal branch of the facial nerve crosses the arch approximately midway between the canthus and tragus and can be damaged as the dissection is taken over the arch. A careful subperiosteal plane provides maximum protection for the facial nerve, which runs in the fascia fairly closely applied to the periosteum of the arch.

One of the most important features of the subperiosteal mid-face lift is the requirement for complete release of periosteum over the zygomatic arch. The periosteum must be released at least to the mid-point of the arch and optimally to the lateral one-third junction of the arch adjacent to the zygomatic temporal suture.

At the level of the arch, the dissection is also carried medially along the inferior orbital rim, which can be easily identified and followed by both its appearance and the natural tendency of the periosteal elevator to catch the edge of the bone and follow the arcus marginalis medially along the inferior orbital rim. The dissection is

carried over the face of the zygoma to the area of the origin of the zygomatic muscle.

After the periosteum is lifted off the arch, the aponeurosis of the masseter muscle is identified as a striated fibrous band emanating from the inferior edge of the zygomatic arch. It is not necessary to cut through the aponeurosis extensively or to dissect over the masseteric fascia; in fact, the local branches of the facial nerve run over the masseteric fascia and are at risk during extensive dissection over the masseter. Rather, it is necessary only to loosen gently some of the attachments of the masseter along the inferior edge of the arch, releasing as well onto the face of the maxilla the vertical attachment, 2 cm downward. The periosteal attachments over the arch and the attachments of the masseteric aponeurosis and ligaments on the vertical medial edge of the masseteric fascia are critical to the success or failure of the surgery; only by completely releasing these attachments can the mid-face be effectively elevated in the subperiosteal plane.

Once the attachments along the lateral orbital rim and zygomatic arch are released, the mid-face is held only by the periosteum over the maxilla. In my experience, these periosteal attachments are not particularly firm. They can be released within the angled elevator using cutting cautery (with care taken to avoid cutting into the plane of the facial nerve) or by inserting long, thin scissors into the plane and gently spreading in a vertical direction to tear the periosteum. A sublabial incision can be made for better visualization of these planes, but I do not find this steps necessary in most cases.

Finally, attention is turned to the lateral canthal angle and superolateral orbital attachments. The outer limb of the lateral canthal tendon is an area of tight attachment of the flap, and these attachments must be released; often there is a tight attachment just below the canthal tendon near the inferolateral angle of the orbit and coming up from the arcus marginalis. These attachments can be palpated with a fingertip or scissors, strummed, and released. The deep limb of the lateral canthal tendon can be visualized as the superficial attachments are released. The deep limb is left intact to minimize canthal dystopia. By grasping the eyelid, the surgeon can feel the deep tendon attachments and verify that they remain intact.

There are tight attachments at the superolateral orbital rim that must be released. They can be palpated with the fingertip. Cutting and spreading the periosteum in the area of these attachments allows them to release; and when the periosteum is completely released, the eyebrow fat pad can be well visualized through the open perios-

teum. Often an endoscopic forehead lift is performed simultaneously, so the entire arcus marginalis is exposed and released through a central brow incision. However, if only the temporal lift is being performed, it is still necessary to release the periosteal attachments along the arcus marginalis medially to the area of the supraorbital neurovascular bundle.

A fingertip inserted into the field is the best instrument for strumming and identifying the remaining attachments. Most often I find residual attachments at the inferolateral orbit and the zygomatic arch; if these attachments are not released, the flap cannot elevate and the surgery will have accomplished very little.

Once the flap is completely mobilized, the surgeon can grasp the deep temporoparietal fascia with toothed forceps and elevate the entire flap so the cheek rises. It is important to recognize that we can always grasp the skin and elevate the flap; but only if the deep layer lifts the flap without resistance is the flap adequately mobilized to allow the surgery to be successful.

Once the flap is adequately mobilized, it is fixated in an elevated position. This is done by placing a suture through the superficial temporoparietal fascia (SMAS) 1 cm inferior to the cut skin edge and suturing the flap to the deep temporalis fascia in an elevated position. The suture in the SMAS can dimple the skin, so it is best placed underneath hair-bearing skin; moreover, an effort can be made to place the suture bite in such a way that it minimizes skin dimpling. I do not believe that a permanent suture offers any more success than a long-lasting absorbable suture; hence I use an absorbing suture such as 3-0 Vicryl to make the attachments. Two sutures can be placed. If the assistant manually elevates the flap to relieve tension, it is easier for the surgeon to tighten the knot. Recognize, however, that it is useless to try to lift the flap under extreme tension. We all know that a surgical wound under tension does not heal. The flap must be adequately released so fixation can be accomplished under normal surgical tension and the surgery can be successful.

Sometimes a cable lift is performed simultaneously. When it is, the cables are placed and fastened to the deep temporal fascia before fixating the temporoparietal SMAS flap.

The short temporal incision can be closed with surgical staples. If the incision was performed above the eyebrow, it is closed in layers in standard fashion, with care taken to evert the wound to decrease the chance of a depressed scar. The hair is washed with warm water and baby shampoo, and no dressings are applied postoperatively.

REFERENCES

1. Sasaki GH, Cohen AT. Meloplication of the malar fat pads by percutaneous cable-suture technique for midface rejuvenation: outcome study (392 cases, 6 years' experience). *Plast Reconstr Surg* 2002;110:635–657.
2. Keller GS, Namazie A, Blackwell K, et al. Elevation of the malar fat pad with a percutaneous technique. *Arch Facial Plast Surg* 2002;4:20–25.

UPPER BLEPHAROPLASTY

EVALUATION

Upper blepharoplasty is a common procedure for aesthetic functional treatment of excess eyelid skin, or dermatochalasis. In fact, often a patient with this condition has a combination of cosmetic and functional complaints. The initial evaluation should include the details of the patient's particular concerns. A handheld mirror is useful to help patients point out eyelid features that are bothersome to them. A complete medical and ophthalmic history, including the use of topical and systemic medications and drug sensitivities, is documented. Specifically ask the patient about aspirin and anticoagulant use. Additional historical questions should focus on dry eye symptoms, eyelid irritation or edema, and visual obscuration.

The complete ophthalmic examination is performed with particular attention to conditions that could adversely affect the outcome of blepharoplasty, including dry eye, meibomian gland dysfunction, keratitis, and corneal dystrophies. In addition to the biomicroscopic examination, one should measure lagophthalmos with gentle lid closure, Bell's phenomenon, and basic tear secretion using Schirmer's filter paper strips after applying a topical anesthetic.

There are specific measurements relevant to dermatochalasis. These are the margin-reflex distance (MRD1), the margin-fold distance (MFD), the margin-crease distance (MCD), and eyebrow position. The MRD1 is the distance from the corneal light reflex (from a penlight on which the patient is fixating) to the upper eyelid margin. This should be normal (3.5–5.5 mm) in patients with isolated dermatochalasis. A low MRD1 value indicates ptosis, and the patient should be worked up

accordingly. Certainly many patients have true ptosis with concomitant dermatochalasis, but both problems must be addressed to achieve an ideal outcome. The MFD is the distance from the upper eyelid margin to the lowest point on the fold of “hanging” upper eyelid skin. This may be zero if the skin is resting on the eyelashes or even a negative number if the skin hangs below the upper eyelid margin. The MCD is the distance from the eyelid margin to the supratarsal eyelid crease. This crease is often hidden under the fold of dermatochalasis and is sometimes asymmetrical between the two eyelids. The normal MCD in a Caucasian woman is about 10–12 mm and in a Caucasian man about 8–10 mm. The Asian lid crease is several millimeters lower.

In addition to the skin and lid crease evaluation, assessment of the upper eyelid fat contours, lacrimal gland position, and brow position is essential to an ideal surgical outcome. The upper eyelid has medial and central fat pads. The lacrimal gland may cause a visible prominence laterally. These findings should be documented and addressed during the procedure. The brow position should be addressed qualitatively. It is important to differentiate brow skin from eyelid skin. If the patient plucks his or her eyebrows, the brow position appears misleadingly high, but close inspection reveals the change in skin thickness and consistency as the transition from thin eyelid skin to thicker brow skin occurs. If the primary cause of the patient’s complaints is brow ptosis, this must be addressed with a brow elevation procedure, not with blepharoplasty.

Visual field testing is generally not necessary prior to cosmetic blepharoplasty. If functional dermatochalasis obscures the superior visual field, it should be documented using automated or kinetic perimetry with the lid in the natural position and then in a taped position. Preoperative photographs should be obtained including full-face views and side or oblique views.

SURGICAL TECHNIQUE

The patient is taken to the operating room or procedure room, and eyelid marking is performed with the patient awake, prior to local anesthetic administration. A fine marking pen is used to define the supratarsal lid crease from directly over the punctum medially to directly over the lateral canthus laterally. The patient’s natural lid crease is often appropriate, but it is sometimes necessary to correct the lid crease position. If the lid creases are asymmetrical, the asymmetry should be corrected. If the lid crease is significantly lower than

the normal MCD for that gender/ethnic group, it should be raised per the preoperative surgical decision-making and discussion with the patient. The lid crease marking then continues laterally to address any lateral “hooding” skin. Once lateral to the lateral canthus, the marking should angle slightly upward, preferably in a skin crease. The length of the lateral skin extension depends on the amount of lateral skin to be excised, but it generally extends 3–10 mm. The medial portion of the excision must be demarcated with particular care owing to potential problems with webbing or scarring. The line should slope upward by about 30 degrees once it is medial to the punctum. The pinch technique is then used to determine the width of skin to be excised from the eyelid. Nontoothed forceps are used to grasp the eyelid skin at the lid crease marking and pinch up the excess skin. A conservative approach should be used, and the brow must not be pulled inferiorly with the forceps. The absolute limits of skin removal are the previously marked lid crease, and the superior limit of the true eyelid skin is about 7–10 mm below the lower eyebrow skin/hairs. It must be noted, however, that the procedure should seldom, if ever, be performed this aggressively. The superior marking is placed with the marking pen, creating a “double gull wing” (Fig. 6-1). A ruler or caliper

FIGURE 6-1. Marking the upper eyelid and incision with a No. 15 blade.



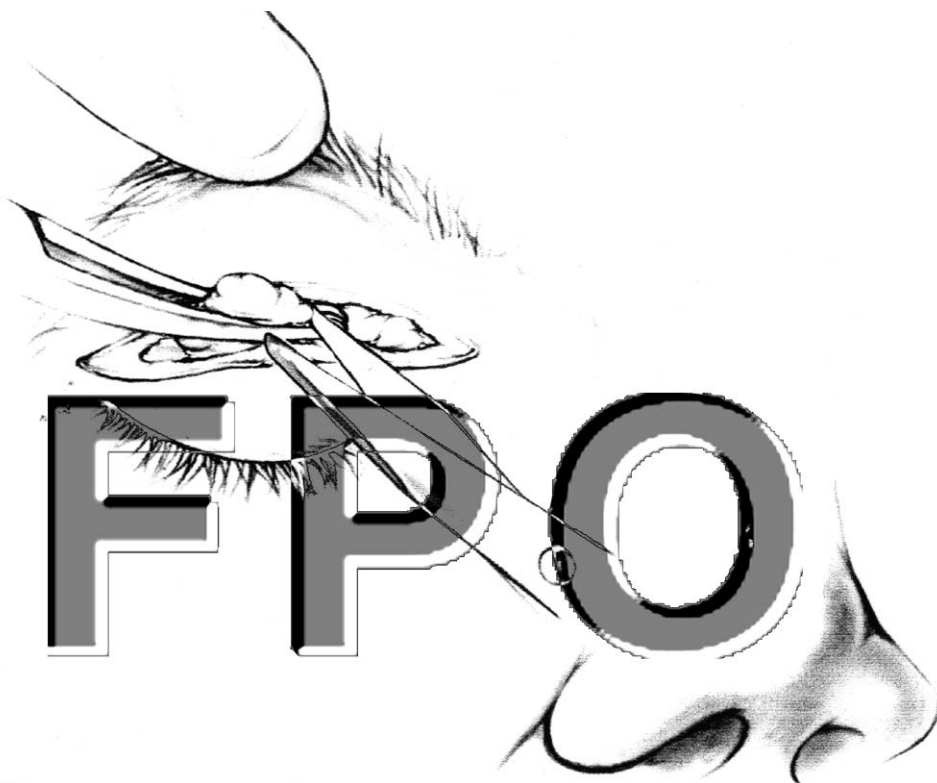can be used to mark a symmetrical pattern on the contralateral eyelid, but the pinch technique should still be used to confirm that the excision does not result in skin shortage. Remember, upper blepharoplasty removes some skin and muscle, but that is not the only goal of the procedure, so markings should be placed conservatively.

Local anesthetic is administered to the subcutaneous tissue. The fat pads or lacrimal gland (or both) should be anesthetized if these tissues are to be reduced or repositioned. The eyelid skin is stretched, and the markings are incised with a blade. The skin/orbicularis muscle flap is then removed with Westcott scissors or cautery/laser, depending on the surgeon's preference (Fig. 6-2). The medial and central fat pads may be removed by gently tenting the overlying septum and opening it with the cautery, laser, or scissors. The fat pad is then removed by the "clamp-cut-cautery" technique. The fat is gently teased through the open septum with forceps or by applying gentle pressure to the globe. The fat is clamped with a hemostat and excised over the hemostat with scissors; and then the base is cauterized (Fig. 6-3). Forceps should be used to hold the stump as the hemostat is released until hemostasis is visually confirmed. This technique is continued until the appropriate amount of fat is removed from the region. Again, a conservative approach is recommended to avoid a superior sulcus deformity. The septum should not be sutured.



FIGURE 6-2. A skin/muscle flap is removed with scissors.

FIGURE 6-3. Orbital fat is clamped with a hemostat and excised with scissors.



If the lacrimal gland is prominent, it should be posteriorly repositioned at this point in the procedure. The dissection is continued through the lateral portion of the blepharoplasty incision by incising the septum. In a small number of cases, significant orbital fat is present between the septum and the lacrimal gland. This fat pad should be carefully excised, exposing the orbital lobe of the lacrimal gland. Dissection should extend to the superior orbital rim. A double-armed 5-0 polypropylene suture is passed in mattress fashion through the inferior portion of the prolapsed gland (Fig. 6-4). Each arm of this suture is then passed posteriorly to anteriorly through the periosteum of the lacrimal gland fossa, just underneath the superior orbital rim (Fig. 6-5). The suture is secured, pulling the lacrimal gland back into the fossa.

Lid crease re-formation can be accomplished by several methods. If the skin is closed with interrupted sutures, an intervening purchase of the preaponeurotic tissue at the superior tarsal border is included in several of the passes across the eyelid crease. If subcuticular lid closure is planned, it is simpler to place several interrupted, buried 6-0 absorbable sutures (Vicryl) through the orbicularis at the inferior incision including the preaponeurotic tissue at the superior tarsal border. This maneuver locks the lid crease in place and facilitates subcuticular closure, which can then be accomplished in a running fashion with 6-0 polypropylene suture. The suture ends are left untied, and the entire incision, including the suture ends, are covered with tincture of benzoin and suture strip tape (Steri-Strips).

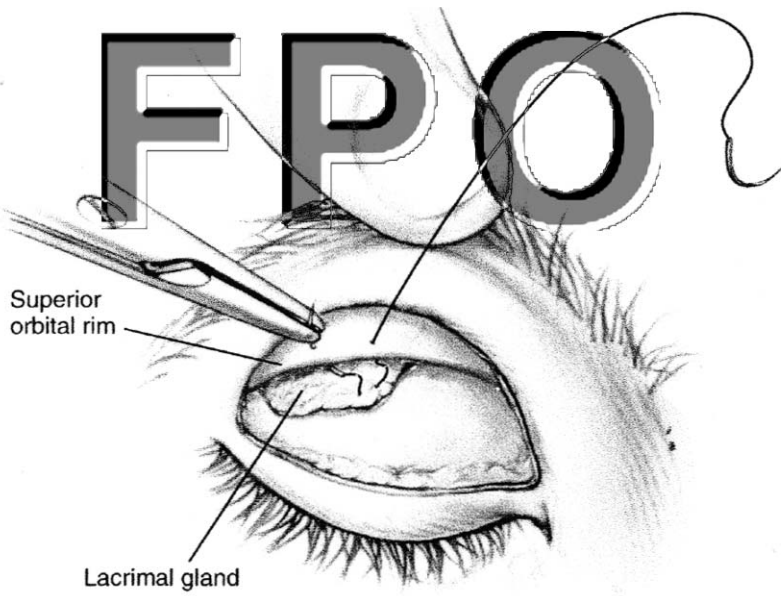
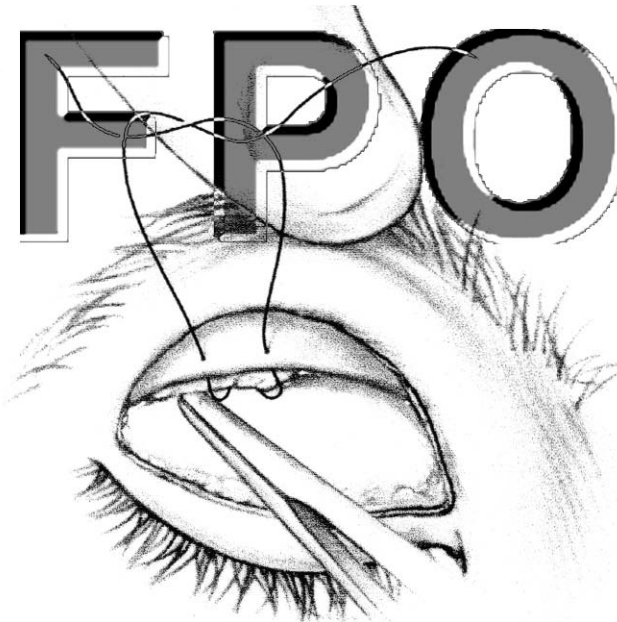


FIGURE 6-4. Double-armed suture is passed through the prolapsed lacrimal gland and through the periosteum.

FIGURE 6-5. Suture tightening pulls the lacrimal gland under the orbital rim.



POSTOPERATIVE CARE

Following surgery, the patient should be instructed to place cold or ice packs on the eyelids for about 15 minutes each hour during the day for 2 days. The patient should not engage in any lifting or bending activities and should sleep with his or her head elevated. The sutures are removed within 5–8 days by first peeling off the strip tape and then pulling one end of the subcuticular suture until the entire suture is free.

LOWER BLEPHAROPLASTY

Concerns about lower eyelid appearance are common in middle aged and elderly patients. These concerns often occur in patients also undergoing evaluation for upper blepharoplasty, so it is beneficial to be able to offer these patients options for improving conditions that affect the lower lids. The primary cosmetic issues of the lower eyelids involve herniated orbital fat and lower eyelid rhytides, which may occur simultaneously or independently in a given patient. The surgeon must consider the patient's age, appearance, skin type, and anatomy. The option of excising or repositioning herniated orbital fat or of performing direct skin excision, CO₂ laser skin resurfacing, mid-face lifting, or a combination of procedures can then be discussed with the patient. In this chapter, we describe techniques for lower eyelid evaluation, excision and repositioning herniated orbital fat, and direct lower eyelid skin excision.

EVALUATION

A complete eye examination is performed, as described in Chapter 6. Particular attention is paid to lower eyelid horizontal laxity and skin laxity. If there is significant laxity of the lower eyelids, a horizontal tightening procedure must be performed with the blepharoplasty. The quality and pigmentation of the skin is assessed. If the skin is lightly pigmented, CO₂ laser is an option for minor skin tightening and reducing fine rhytides. If there are major rhytides and excessive skin redundancy, direct skin excision should be considered.

The lower eyelid has medial, middle, and lateral fat pads. Herniated fat pads are identified, palpated, and documented using a scale

consistent for that physician. We use a 0 to 4+ scale to describe the size of each pad. Gentle retropulsion of the globe often makes the fat pads more obvious. If there is significant herniated fat, a transconjunctival approach to excision is recommended. The examiner should also palpate and consider the position of the globe relative to the inferior orbital rim and the shape of the maxillary and zygomatic bones inferior to the fat pads. Close inspection of the conjunctival fornix should exclude active cicatricial disease.

The lower eyelid is an extension of the mid-face and is evaluated as such. Nasojugal grooves, festoons, descent of the malar fat pads, and mid-facial skin laxity are all assessed. A handheld mirror is used to allow the patient to point out bothersome features. The lower eyelids are inspected with the patient's mouth open as well to check for possible retraction. External photography should include full face, oblique, and side views to show the extent of the fat herniation.

SURGICAL TECHNIQUES

Transconjunctival Lower Blepharoplasty

Local anesthesia containing epinephrine is injected into the conjunctival fornix. If a retrobulbar anesthetic is used, it should not contain epinephrine, as prolonged diplopia may result. Some surgeons elect to forego a retrobulbar block and just infiltrate the anterior portions of the herniated fat pads. Either technique is acceptable.

A Desmarres retractor is used to pull the eyelid away from the globe, and a transconjunctival incision is made in the fornix, approximately 12 mm below the lid margin (Fig. 7-1). This incision can be made with a variety of instruments, such as a needle tip monopolar unit, radiofrequency unit, CO₂ laser, high-temperature cautery, or a blade. The blade technique is effective but offers the poorest hemostasis and is therefore not recommended. The retractor is always held in a position to protect the eyelid from the incising device. The septum is then incised, and herniated orbital fat becomes visible. Gentle pressure on the globe helps define and prolapse the fat into the wound once the septum is incised. Care is taken to avoid damaging the inferior oblique muscle, which originates from the medial aspect of the inferior orbital rim and is often visible between the medial and middle fat pads.

The fat is excised using the "clamp-cut-cautery" technique, which involves clamping the fat pad with a hemostat, cutting the fat above the hemostat with Westcott scissors, and cauterizing the base (Fig. 7-2).

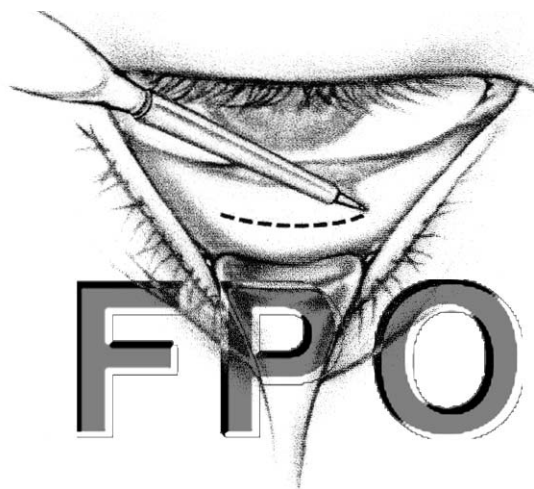
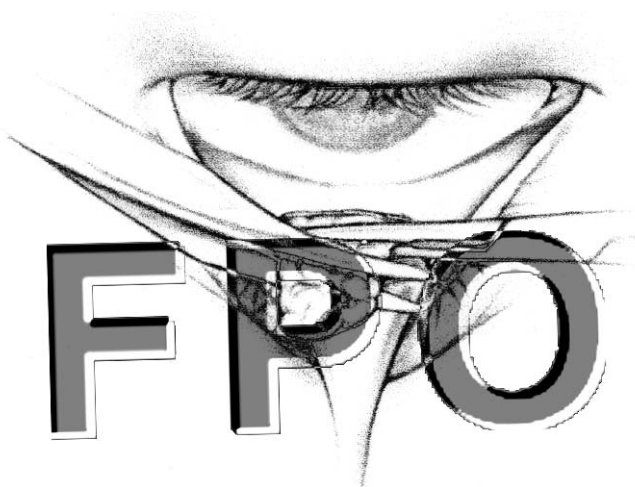


FIGURE 7-1. Transconjunctival incision made with an electrocautery unit.

FIGURE 7-2. Orbital fat is removed with scissors after being clamped with a hemostat.



Forceps are used to grasp the fat below the hemostat prior to releasing it to confirm hemostasis. This technique is used to remove all the herniated fat according to the preoperative plan. The temporal pad is often elusive, and particular attention should be paid to locating and excising this pad. Overexcision of lower eyelid fat is avoided because it would create a hollow lower eyelid appearance. Removing a significant orbital volume can contribute to a superior sulcus deformity as well.

It is possible to improve the appearance of a nasojugal groove by dissecting a medial subperiosteal pocket under the groove. The medial fat pad is then dissected as a narrow pedicle and mobilized into the subperiosteal space. Double-armed 6-0 nylon sutures are threaded through the fat pad in a mattress fashion (Fig. 7-3) and then passed through the full thickness of tissue, where they are tied over the skin of the nasojugal groove (Fig. 7-4). This pulls the pedicle of fat under the groove and fills it in. The suture can be removed in about 5 days. There is a risk of diplopia with this technique, so the surgeon must be sure to discuss this possibility with the patient. Dissecting the pad thoroughly to form a relatively free pedicle reduces the risk of this complication.

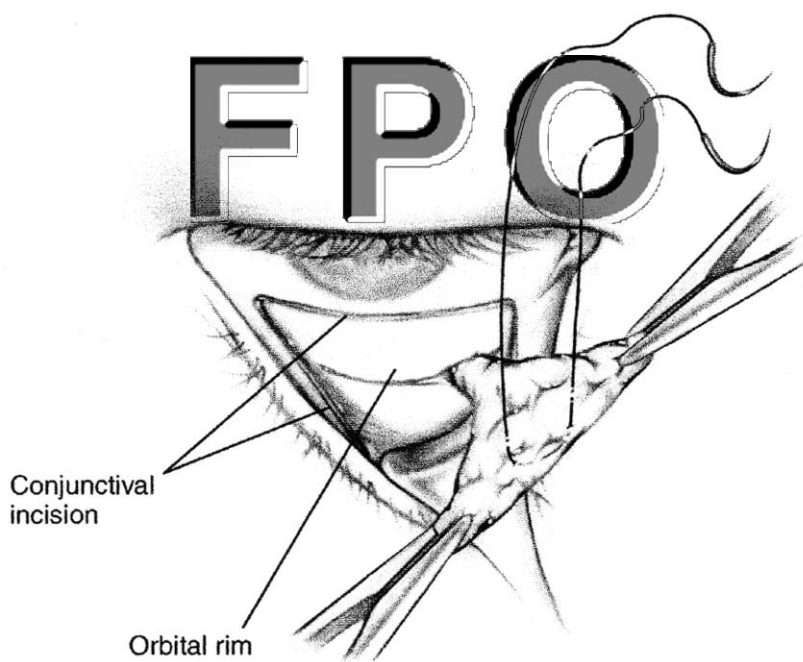
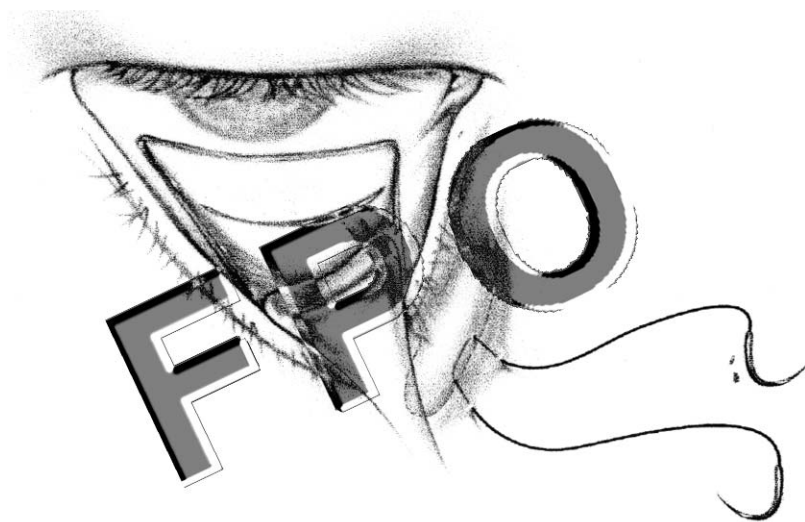


FIGURE 7-3. Medial fat pad is fashioned into a T shape.

FIGURE 7-4. Fat is transposed subperiosteally to fill the nasojugal fold.



Lower Eyelid Skin Excision

Skin excision may be performed separately or in conjunction with herniated orbital fat excision. Either way, we recommend that the fat be excised by a separate, transconjunctival approach to reduce the risk of lower eyelid retraction associated with transcutaneous skin/fat removal.

A fine marker is used to draw an infraciliary incision line about 1.5 mm below the lash line. The marking extends laterally and slightly downward past the lateral canthus. An epinephrine-containing local anesthetic mixture is administered to the skin. A blade is used to incise the skin temporally, and Westcott scissors can undermine and incise the remainder of the infraciliary line (Fig. 7-5). A skin flap is dissected inferiorly with the scissors. We prefer a “skin only” flap to smooth the fine lines of the lower eyelid and reduce the risk of retraction. The skin flap is advanced superiorly and slightly laterally, and an overlap technique defines how much skin should be excised (Fig. 7-6). The patient should be asked to open his or her mouth and look upward to ensure an extremely conservative approach to the skin removal. The skin is excised first horizontally with the scissors, and then a vertical excision removes a second triangle of skin laterally. Interrupted 6-0 plain gut suture is used to close the skin. Often, lateral canthal tightening via a tarsal strip or plication-type procedure is used in conjunction with lower eyelid skin removal to reduce the risk of retraction even further.

Patients can be given ophthalmic ointment following lower blepharoplasty. The eyes should not be covered by a patch. Ice packs are useful for minimizing edema. Patients are instructed to be aware of symptoms of the rare complication of retrobulbar hemorrhage and to consider it an emergency should it occur.


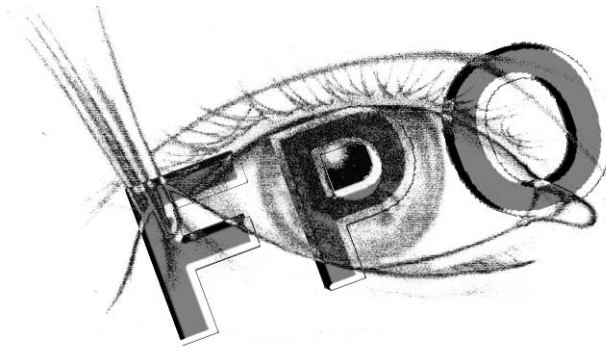


FIGURE 7-5. Starting temporally, scissors are utilized to raise a skin flap.

FIGURE 7-6. Skin is advanced superiorly and laterally to determine the amount of excess present.



LASER SKIN RESURFACING

The use of lasers to reduce the effects of age and sun damage to facial skin has gained widespread acceptance (Fig. 8-1) Carbon dioxide (CO₂) and erbium lasers produce controlled cutaneous exfoliation with limited damage to surrounding tissue. Their wavelengths are highly absorbed by water, the main cellular constituent.

CO₂, erbium, or combined CO₂/erbium lasers are available. Young patients with few, shallow rhytids and patients who have more pigment are often treated with the erbium laser. Older individuals with deep rhytids are usually treated with the CO₂ laser. In general, faster healing follows treatment with the erbium laser, particularly when low fluence is used on shallow rhytids; when higher fluence is applied, the healing time tends to be longer.

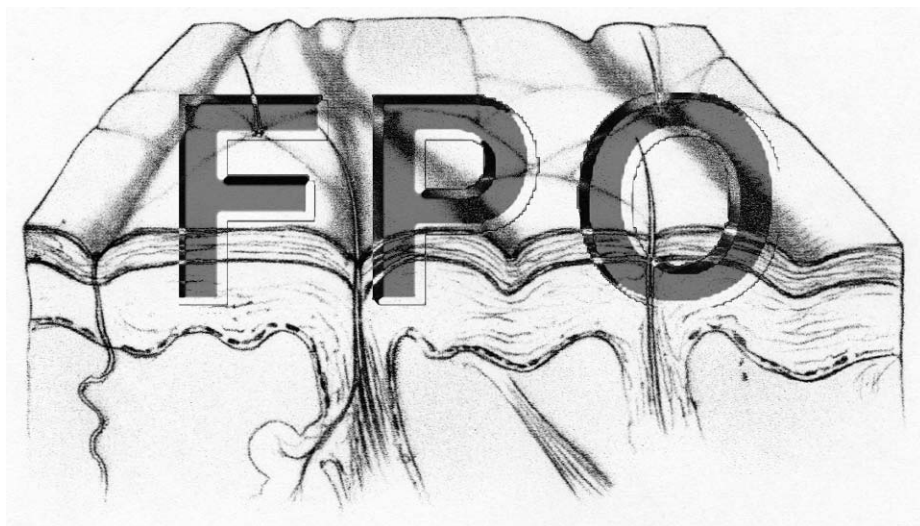

FIGURE 8-1. Skin with wrinkles.

The lasers also affect dermal collagen tightening differently. Patients treated with the CO₂ laser tend to experience significant remodeling of collagen and tightening of skin, whereas those treated with the erbium laser experience only minimal wound contracture (Fig. 8-2). To achieve more dramatic results and remove deep rhytids, deeper treatment with higher fluence is the rule, but patients must expect longer healing times.

EVALUATION

A detailed history with emphasis on wound healing and scar formation is imperative. The surgeon must know if a patient has a history of abnormal wound healing or skin disorders. Serious healing problems can result if there is a history of collagen vascular diseases, keloid formation, or immunologic abnormalities. The epithelium of the adnexal structures is the source of reepithelialization of the lasered skin. Isotretinoin (Accutane) and prior facial irradiation inhibit this process. Use of isotretinoin within 1 year of resurfacing is a contraindication to the procedure.

A patient's ethnic background and degree of pigmentation can have an influence on the outcome of resurfacing. The surgeon must distinguish the patient's normal, or "baseline," pigment from acquired

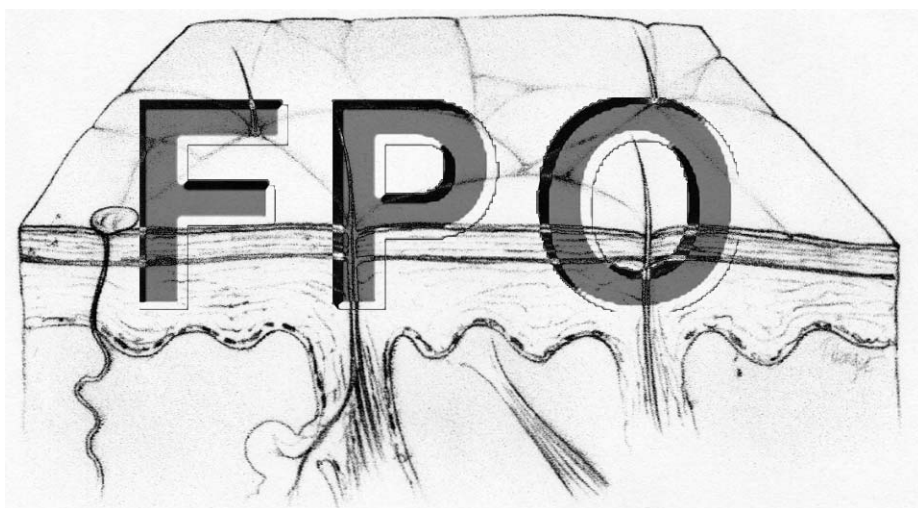


FIGURE 8-2. Skin after CO₂ laser resurfacing, with reduction of wrinkles and improved collagen structure throughout the dermis.

pigmentation due to sun exposure or other conditions, including melasma. Extremely light-skinned individuals are more prone to have prolonged erythema postoperatively. Conversely, patients with dark baseline skin types have a higher incidence of both hyperpigmentation and hypopigmentation.

In many patients, laser alone cannot achieve the desired skin tightening and wrinkle reduction. Other procedures are sometimes needed in conjunction with the laser treatment or at some later time. To rejuvenate the eyelids, endoscopic forehead lift and transconjunctival blepharoplasty are safely performed at the same time as laser application. The tissues retain adequate vascularity with these procedures.

Some surgeons recommend treating the skin prior to laser to improve postoperative healing and reduce inflammatory pigmentary changes. However, a recent study indicated that preoperative treatment using either 10% glycolic acid or 4% hydroquinone and 0.025% retinoic acid did not affect postoperative hyperpigmentation in patients regardless of the skin type. The probable reason is that the epidermal melanocytes, which are affected by these agents, are destroyed by the laser and therefore do not contribute to the pigmentary changes.

If a patient has a history of facial herpes, the surgeon should pre-treat the patient with antiviral medicine such as acyclovir (Zovirax),

famciclovir (Famvir), or valacyclovir (Valtrex). An appropriate treatment would be valacyclovir 1000 mg PO bid (or famciclovir 500 mg PO bid or tid) starting the day of the laser treatment and continue for 7–10 days until complete reepithelialization occurs. If the patient does not have a history of herpetic outbreaks, appropriate antiviral prophylaxis includes valacyclovir 500 mg bid or famciclovir 250 mg bid. If the patient has no history of a herpetic outbreak and no treatment of the perioral area is planned, prophylaxis is not recommended.

All patients are given antibiotic pretreatment, usually cephalexin (Keflex) 250 mg PO qid for 10 days or cefadroxil (Duricef) 500 mg PO bid. If the patient has a penicillin allergy, azithromycin (Zithromax) 500 mg PO on day 1 and then 250 mg PO on days 2–6 or ciprofloxacin (Cipro) 250 mg PO bid for 10 days are reasonable alternatives.

Patients must be made aware of the possibility of prolonged healing and erythema, and they must follow detailed postoperative instructions. The postoperative course typically involves more care from the physician than with most surgical procedures.

TECHNIQUE

All instruments, including the protective eye shields, should have a dulled metal surface. Areas that are not to be treated should be protected with wet towels. Laser goggles used by personnel involved in the operation should be wavelength-appropriate. A high quality smoke evacuator is essential to reduce the plume created by the laser treatment.

There is a risk of the laser igniting the supplementary oxygen. If the patient is under general anesthesia, additional protection is needed to avoid lasering the endotracheal tube and igniting the flammable gases. The agents used for skin preparation should be of a non-flammable nature.

Laser settings must be verified between the surgeon and the technician. The laser should be tested prior to use on a tongue depressor to ensure its proper pattern and function.

PERIORBITAL RESURFACING

Prior to starting the application of laser energy, the outlines of the area to be ablated are outlined with a marking pen. For periorbital resurfacing the lower lids are being treated, as well as the area of

the crow's feet. A 2 mm strip of tissue is left untreated in the area just underneath the lashes, a practice that minimizes the chance of developing a postoperative ectropion.

A Coherent UltraPulse laser with a power setting of 250 mJ and a density of 5 is used for these patients. The ablated tissue is gently removed with a damp 4 × 4 gauze. Rubbing hard enough to produce a raw skin surface should be avoided, as it tends to produce prolonged postoperative hyperemia. The area is then thoroughly dried with a dry 4 × 4 gauze.

A second pass with the same power settings is then employed on the lower eyelids. The second pass extends slightly past the border of the original pass to blend or feather the effect into the untreated area. A coating of Aquaphor ointment is then applied to the lasered area. Ablated tissue from the final pass is not removed prior to applying the ointment.

PERIORAL RESURFACING

CO₂ laser skin resurfacing in areas other than the eyelids is performed with an UltraPulse laser with a power setting of 300 mJ and a density of 5. In the perioral area it is important to overlap the vermilion border by several millimeters and protect the teeth from the laser energy.

Prior to applying laser energy, the area to be treated is outlined with a marking pen. The first pass of the laser ablates the epithelium. Various patterns of laser ablation can be utilized depending on the surgeon's preference. In the lower lip area, the vermilion border is again overlapped.

After the first pass is completed, the ablated tissue can be removed with a damp 4 × 4 gauze. It is important to not rub hard enough to produce raw, abraded tissue, as it tends to produce prolonged postoperative hyperemia of the skin. The treated area is then dried prior to commencing the second pass.

The same energy settings are used for the second pass, which is carried slightly past the boundary of the original pass to produce "feathering." If necessary, a third pass can be performed after the ablated tissue from the second pass is gently removed.

When the final pass is completed, a thin coating of Aquaphor ointment is placed. The ablated material from the final pass is not removed prior to placing the ointment.

POSTOPERATIVE CARE

For the first 1–2 days the treated area should be kept cool, but not wet, by applying ice compresses for 15 minutes of each hour. On the first day following laser, gentle cleaning is performed in the morning and evening with a mixture of one part hydrogen peroxide and three parts warm water to remove extra crusting and debris. Aquaphor is reapplied several times throughout the day. This regimen is continued until the epidermis is healed completely, usually by 7 days.

The primary postoperative goal is to facilitate healing of the epithelium. Pain, serous discharge, and crusting occur in all patients. Mild “pinpoint” bleeding often occurs following erbium resurfacing. An “open” technique of wound care in which the lasered skin is thoroughly and continuously covered by a suitable ointment (Aquaphor) is appropriate for most cases. The epidermis tends to regenerate faster and heal with fewer complications if the wounds remain clean and moist.

A narcotic analgesic is often necessary to maintain patient comfort for several days, particularly following full-face laser. If the treatment is local, such as to the periorbital area, acetaminophen alone may suffice. An oral antihistamine may reduce pruritus.

Erythema can persist for a few months, and prolonged inflammation increases the chance of pigmentary changes. Hydrocortisone 1–2% can be utilized to lessen erythema but should not be started for at least 1 month after laser treatment. After the epithelium has healed, camouflaging cosmetics may be applied until the redness has subsided. Avoidance of sun exposure is necessary for several months, at least until complete resolution of the erythema. Complete sun block must be applied when outdoors while erythema persists.

Postinflammatory hyperpigmentation occurs 1–2 months following laser in approximately one-third of patients. This risk is greater in patients with dark skin. Pigmentary changes are usually transient. Regimens to reduce hyperpigmentation include bleaching agents such as hydroquinone, kojic acid, and azelaic acid, with or without facial glycolic acid or trichloroacetic acid peeling treatments. Care must be taken to avoid inducing erythema with these treatments, which can result in increased hyperpigmentation.

During the healing period, the newly epithelialized skin is hypersensitive to allergens in topical preparations and the air. Even after the epithelium has healed, the skin remains hypersensitive. The use of hypoallergenic and fragrance-free soaps is recommended.

FACIAL COSMETIC BOTOX

Botox is a trade name of botulinum toxin type A, a purified, sterile neurotoxin complex produced from a strain of *Clostridium botulinum*. This chemical blocks neuromuscular conduction by binding to motor nerve terminals and inhibiting release of acetylcholine. Following intramuscular injection, the result is temporary chemical denervation-induced muscle paralysis.

Botox, used since 1980 to treat strabismus and blepharospasm, has been approved by the U.S. Food and Drug Administration (FDA) for treatment of strabismus and blepharospasm associated with dystonia, including benign essential blepharospasm or seventh cranial nerve disorders in patients 12 years of age and older. It has also been used successfully in the treatment of cervical dystonia and migraine headaches. Its use for forehead wrinkles was described in 1989. The successful use of Botox for cosmetic purposes has led to its application for numerous clinical conditions. It gained FDA approval in 2002 for temporarily improving the appearance of individuals with glabellar lines (frown lines) associated with corrugator or procerus muscle activity in adult patients.

The most common cosmetic applications for Botox are the reduction of glabellar frown lines, crow's feet, and horizontal forehead lines. Other less common uses include reduction of neck lines, mental creases, and nasolabial folds. Botox can also be used to treat facial asymmetry. Recently it has been utilized for the management of chronic tension headaches and hyperhidrosis.

Other formulations of botulinum are available and may provide similar results. Myobloc (botulinum toxin type B; Elan Pharmaceuticals, South San Francisco, CA, USA) is indicated for treatment of cer-

vical dystonia to reduce the severity of abnormal head position and neck pain. Many physicians use this product in a similar manner to treat facial rhytids due to the hyperfunction of certain muscles.

CLINICAL EVALUATION

Facial lines and wrinkles (rhytids) have numerous etiologies. Sun damage, skin atrophy, loss of dermal elasticity, and frequent or continuous muscle activity can contribute to rhytid formation. Wrinkles secondary to muscle action appear perpendicular to the action of the muscle. A reduction of these wrinkles may be apparent when the muscle is relaxed.

Facial rhytids may be described as static or dynamic. Static rhytids are present when the face is relaxed. Dynamic rhytids appear or are accentuated during facial animation. Botox is particularly beneficial for reducing the appearance of dynamic rhytids in certain areas of the face, particularly the forehead and periorbital regions. For example, by weakening the frontalis muscle Botox reduces the appearance of horizontal rhytids during attempted brow elevation. Static rhytids that were initially present are also likely to be reduced, although not necessarily eliminated.

During evaluation, patients often direct the physician to the areas that concern them. Many patients do not realize that Botox weakens muscles, and many expect that the injections can reduce all types of wrinkles. The physician should point out, with the use of a mirror, the areas that can be altered with Botox administration. By having the patient raise the eyebrows, furrow the brows, and smile, the physician can demonstrate the accentuation of rhytids during facial animation. Patients should understand that these muscles are the ones affected by Botox injections. If a patient has other cosmetic concerns, the physician might discuss how adjunctive procedures might be combined with Botox treatment.

DILUTION

According to the manufacturer, Botox should be diluted with preservative-free 0.9% saline. The vial is vulnerable to surface denaturation, so the surgeon must be cautious not to shake or agitate the bottle when diluting the solution. The saline should be gently introduced into the vial to prevent foaming of the Botox solution.

The amount of dilution varies with the site treated. High concentrations (50–100 units/ml) theoretically give a more localized effect with fewer side effects. If a large volume of solution at lower concentration (5–25 units/ml) is injected, there is a greater possibility that the material will diffuse over a greater surface area. This diffusion of material may result in a broader area covered or may cause side effects (e.g., eyelid ptosis).

Once the vial is diluted, Botox tends to lose its efficacy gradually, beginning at 12 hours, although some surgeons claim that the diluted Botox retains efficacy for up to 1 month. The manufacturer recommends use of reconstituted Botox within 4 hours.

CONTRAINDICATIONS

Botox is contraindicated in patients who are known to be hypersensitive to the ingredients including human albumin and saline, those with muscular or neurologic diseases, and pregnant women. Aminoglycosides are a relative contraindication because they interfere with neuromuscular transmission and potentiate the effects of Botox.

PROCEDURE

The volume and concentration of Botox injected depends on the area being treated. The dilution depends on what location is treated and the extent of muscle paralysis desired. A vial contains 100 units of Botox. Typically, 2 cc of saline is slowly added to the vial, providing 100 units of Botox/2 cc (5 units/0.1 cc). The surgeon should use a tuberculin syringe with a 30-gauge needle for all injections. Do not use the same needle used to draw up the Botox solution as it will be slightly dulled and more painful for the patient. At the typical site, 0.1 cc of solution is injected. Prior to and after injection, it may be beneficial to cool the treatment area with ice packs because some patients complain of brief, mild discomfort and stinging. Topical anesthesia may be used but is not necessary.

Glabellar frown lines can be treated effectively for cosmetic reasons. Typical injections are placed above the medial brow (directly into the corrugator muscles) and between the brows (into the pro-

cerus muscle) (Fig. 9-1). The dilution depends on the thickness of the muscle. Usually men require more units than women. Generally, 3–7 units/site are administered at each injection site. Injections should be symmetrical to achieve a balanced look. Up to 80 units may be used in the glabellar region. For most patients, five injections of 5 units each (total 25 units) provide results with which patients are satisfied.

When treating crow's feet, two or three injection sites lateral to the lateral orbital rim are used (2–5 units/site). The patient is asked to smile, and the center of the canthal creases is marked. The first injection is given at the canthal crease. The second and third injections are applied approximately 1 cm above and below the first. For most patients, 10 units per eye provide optimal results.

Treatment of forehead wrinkles provides excellent results in most patients (Fig. 9-2). Several treatment methods exist, and the physician must determine which is best for a particular patient. One technique (described in the video) involves injections directly into a rhytid or just above and below a rhytid. This technique may be best suited for patients with a small number of rhytids or wrinkles localized to one small region, such as the central forehead only. A total of four to six injections (5 units/injection, 20–30 units total) should provide good results.

For a patient with diffuse transverse forehead rhytids, a more generalized approach might suffice. Usually four injections (5 units/injection, 20 units total) provide broad coverage. Each injection is given approximately halfway between the brow and hairline. The two medial injections are given along a vertical line through the medial edge of the eyebrow. The two lateral injections are given along a vertical line through the lateral canthus.

At therapeutic doses, the initial effect of Botox for all these locations can occur 2–3 days after injection. Maximal weakness occurs within 1 week. In general, the smaller the dose of Botox, the longer it takes to see the results. The effects usually last 3–5 months in patients who undergo the treatment for cosmetic purposes. Patients can be reexamined 1–2 weeks after the initial treatment; if additional injections are necessary, they may be provided from the original vial. Repeat injections are given every 3–6 months.

One must be aware that Botox does have immunogenic properties. For neurologic patients, it has been estimated that nearly one third of treatment failures are due to antibody formation. Failure is rarely seen in blepharospasm patients because such a low dose is administered. Patients at risk of developing antibodies are those given

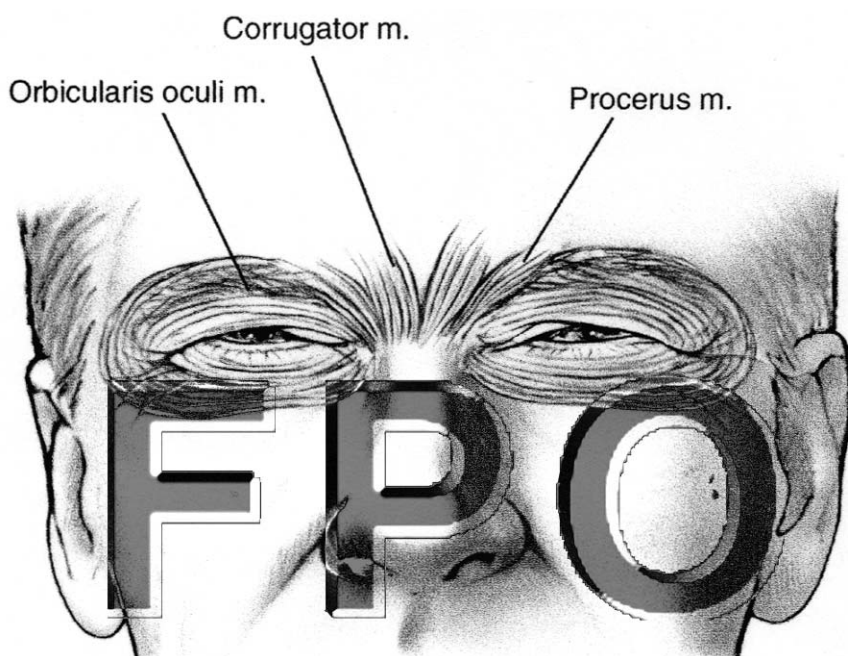


FIGURE 9-1. Important muscles in the glabellar region.




FIGURE 9-2. Areas commonly treated with cosmetic Botox. A, transverse forehead rhytides; B, glabellar rhytides; C, crow's feet.

the toxin at doses of more than 100 units per session, booster injections within 30 days of initial injection, or injection into the systemic circulation. For these reasons, it is probably best to give patients the lowest possible dose needed to achieve the desired effect. Higher doses do not result in a better or longer-lasting effect and may predispose to antibody formation.

As seen in the accompanying video, cosmetic Botox can be used to treat glabellar and forehead rhytides. A dilution of 5 units/0.1 cc is utilized. In the glabellar region, 5 units are injected directly into five sites: two in the right corrugator, one in the procerus, and two in the left corrugator for a total of 25 units.

For a patient with transverse central forehead rhytides, Botox (5 units) is injected above and below several of these rhytides. This relaxes the frontalis muscle and greatly diminishes the rhytides. The area should not be massaged after injection, but gentle pressure can be applied to stop any bleeding that is present. Typically, injection must be performed every 3–6 months.

COMPLICATIONS

Although adverse reactions and complications are uncommon and reversible, they must be disclosed to the patients. Such effects include ptosis, ectropion, tearing, keratitis, and rarely entropion and diplopia. The injected volume should be minimal to reduce the risk of ptosis. When the physician injects the upper eyelids for spasm, Botox should be placed into the pretarsal orbicularis to diminish the risk of ptosis. Some claim that the injected areas should not be manipulated for several hours after injection so Botox can bind to its receptors. Moreover, they note that the patient should remain vertical for 2–3 hours to reduce the risk of ptosis.

LIP AUGMENTATION

Lip augmentation is a frequently requested facial cosmetic procedure. The desire for it is usually motivated by aesthetic concerns. A recurring goal in cosmetic surgery has been to achieve softer, fuller, rounder, younger-looking lips. Many techniques have been described to fulfill this goal. This chapter presents the use of AlloDerm® (LifeCell, Branchburg, NJ, USA) to achieve fullness of the lips.

ETIOLOGY

Young patients pursue fuller lips because of labial hypoplasia or for purely aesthetic reasons. Older patients have decreased elasticity and overall volume of the lips. This can result in overall labial ptosis with perioral and labial rhytides. Congenital conditions such as cleft palate can also result in apparent labial hypoplasia, and pseudoentropion of the lip can occur when natural dentition is lost. The patient experiences decreased lip projection and overall lip lengthening. All these conditions can be corrected with augmentation to achieve more aesthetically pleasing lips.

Anatomic landmarks are important for aesthetic lip evaluation. The lower face and lip region can be separated into thirds (Fig. 10-1). The distance from the subnasion to the upper interlabial gap is one-third of the lower facial third. The distance from the lower interlabial gap to the menton comprises two thirds of the lower facial third. Finally, the upper and lower lip vermilion borders combined should occupy one-fourth of the lower third of the facial height from the subnasion to the menton. Furthermore, the upper lip height/lower lip height ratio is 1.0:1.5.

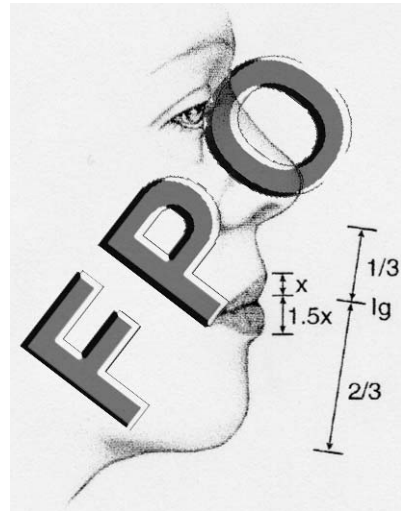
CLINICAL EVALUATION

It is important to address the specific patient's needs when planning lip augmentation. Discussing the risks, complications, and benefits of the procedure lessens any apprehension the patient may have pre- and postoperatively. As mentioned for endoscopic foreheadplasty in Chapter 2, it is recommended that the patient look in the mirror to determine exactly what is desired. This gives the surgeon an opportunity to discuss realistic surgical outcomes. The distance from the subnasion to the interlabial gap and between the interlabial gap and the menton is measured. Photographs are taken in repose and from the side for documentation.

MEDICAL MANAGEMENT

A number of techniques are available for labial augmentation. Silicone injections were once available but are no longer approved for lip augmentation in the United States. More commonly used are filler materials such as collagen, Dermalogen, Cymetra, Perlane, and Restylane (the latter two are under investigation and not currently approved by the U.S. Food and Drug Administration (FDA)). Bovine collagen comes as Zyplast and Zyderm, and the patient must be skin-tested before usage. Cymetra is the injectable form of AlloDerm and has properties similar to those of AlloDerm strips. Most patients with fillers require further augmentation within 4–6 months of the initial treatment.

FIGURE 10-1. Normal proportions of the lower face.



SURGICAL MANAGEMENT

Surgical treatment of lip augmentation can include direct lip lift, vermillion excision, mucosalplasties, and implantation of autogenous materials (dermis, fat, fascia, superficial muscular aponeurotic system, galea, breast capsule tissue, palmaris tendon) and alloplastic materials (Gore-Tex®). We use allograft material called AlloDerm, which is a transplantable allogenic cadaveric dermis. The human donor skin via a patented process strips immunogenic cellular elements from the epidermis and dermis, making the material immunologically inert. Hence skin testing is not necessary. AlloDerm has been used extensively for grafting since 1992.

Local nerve blocks are performed in the mucosa of the upper lip using 2% lidocaine with 1:100,000 epinephrine on both sides of the frenulum. The lateral commissures of the upper lip are also blocked. This procedure is typically done in conjunction with intravenous sedation. Preoperative measurements of lateral lip heights, right and left philtrum heights, and central lip height are recorded. The distances from the commissures are also noted. An incision is made at one commissure about 5 mm from the corner. A buttonhole incision is made in the corner, with dissection carried in the submucosal plane superficial to the orbicularis oris muscle. This dissection is carried for a short distance along the vermillion border. A cob elevator is then inserted in the tunnel, and gentle blunt dissection is carried to the contralateral commissure. Gentle traction of the lip can make this

journey smoother. Once on the other side, an incision is made in a similar fashion in the other corner. The cob elevator is pulled through the other end. This tunnel is widened with a freer elevator to accommodate the AlloDerm strip.

A 3 × 5 cm AlloDerm strip is hydrated for 5 minutes in sterile saline solution. A central V-shaped incision is made to accommodate cupid's bow (the central portion of the lip). All four corners are trimmed to allow easier access in the tunnel. A tendon passer is threaded through the tunnel. The AlloDerm sheet is grasped with the tendon passer and pulled through the tunnel, positioning it appropriately. It is useful to stretch the lip gently in an accordion fashion to smooth out the AlloDerm. The corners are trimmed, and absorbable sutures are used to close the commissures, making sure to grasp a piece of the AlloDerm in the closure.

Postoperatively, the patients are given nonsteroidal antiinflammatory drugs for pain. If there is a history of herpes simplex infection, famciclovir is given 3 days before and 3 days after the surgery. Ice compresses are started immediately after the surgery and placed intermittently for about 15–20 minutes each hour for 2 days. Edema is expected for the first week. Substantial volumetric loss occurs over 3–6 months, with less substantial volumetric loss during the next 6 months with more stable clinical results. The lips can be further augmented with a filler material if needed. The use of these surgically implantable materials for lip augmentation can provide overall improvement in the labial appearance.

SOFT TISSUE AUGMENTATION

- César A. Sierra, MD

*Department of Ophthalmology
Yale University School of Medicine
New Haven, Connecticut*

Many materials and approaches have been used throughout the years to address the challenging issue of soft tissue augmentation. At the end of the eighteenth century, interest in techniques other than those involving large reconstructions with flaps or grafts intensified, and the subject began to be studied in more detail. However, less than favorable results were reported owing to the lack of reliability and longevity of the substances used in such cases. This erratic use of unpredictable materials led to a skewed perception of soft tissue replacement for many years.

During the last three decades the field has advanced to a precise combination of art and science with the development of reliable, safe materials. Three major biomaterials are the focus of the discussion here. Bovine collagen and acellular dermal matrix are readily available in the United States. Since 1976 we have been able to study the success of collagen as a biomaterial for soft tissue augmentation. More recently, LifeCell Corporation (Branchburg, NJ, USA) developed acellular dermal matrix sheets that have been used extensively as grafts, spacers, or fillers. The micronized, injectable form (Cymetra; LifeCell)

is also utilized for facial rejuvenation and reconstruction with several alleged benefits over collagen. Finally, stabilized hyaluronic acid (Restylane Fine Lines, Restylane, Perlane; Q-Med AB, Uppsala, Sweden) is a nonanimal filler used widely throughout the world with apparently excellent results.


Many areas of the face are amenable to soft tissue augmentation (Fig. 11-1). Lip enhancement is becoming popular in patients 25–50 years old. It gives a more luscious look in younger patients and fuller contour in those who have atrophy of the body of the lips. Lifting of the nasolabial folds plumps the area of tissue loss and affected by gravitational forces, giving a younger, fuller look. Occasionally, volume replacement serves to complement a facelift when tightening is not enough to correct fully atrophy of the nasolabial folds. In some patients, we recommend treatment of the nasolabial folds along with lip enhancement and lifting of the oral commissure, or marionette lines, for better aesthetic results of the entire perioral unit. Acne scars also respond well to dermal fillers, especially when thicker material (Cymetra or Restylane) is used as close to the dermis as possible. Cheek augmentation is helpful especially in patients with human immunodeficiency virus (HIV)-related soft tissue atrophy. Soft tissue replacement treatment in the glabellar and forehead areas is usually not recommended with thick, large-particle fillers because of the risk of central retinal artery occlusion and blindness.

COLLAGEN

Collagen has been available to the surgeon in several preparations. Autologous collagen dispersion (Autologen; Collagenesis, Beverly, MA, USA) is processed from the skin of the patient. Surgery is required to harvest the collagen; and, although it seemed an excellent choice for tissue replacement, the production of Autologen ceased owing to the complex procedure of harvesting, processing, and shipping the tissue back to the surgeon. A homologous acellular suspension of collagen (Dermalogen; Collagenesis) is processed skin from tissue banks. It does not require additional surgery or skin testing prior to its use. Finally, highly purified bovine collagen is the material most surgeons have used for the last two decades, and it remains the standard by which other injectable soft tissue fillers are measured.

Testing for allergy to bovine collagen is required, as 3% of the population show a positive reaction. A skin test is easily administered, injecting a 0.1 cc test dose of bovine collagen in the dermis of

FIGURE 11-1. Soft tissue augmentation with a variety of materials can be used in the following regions. A, glabellar frown lines; B, nasolabial fold; C, vermillion border; D, acne scars; E, perioral lines; F, vertical lip lines; G, marionette lines.



the antecubital fossa. A positive skin test response is defined by an area of induration, erythema, edema, tenderness, or itching that lasts more than 6 hours or develops 24 hours or more after testing. Up to 30% of the allergic patients react later than 3 days after inoculation; therefore everyone should be monitored for a month for an allergic response. Both surgeon and patient must understand the possibility of developing an allergy even in the absence of a positive skin test (1% of treated patients). For this reason some advocate double skin testing to confirm the results.

Zyderm I (McGhan, Santa Barbara, CA, USA) is composed of a 35 mg/ml suspension of bovine collagen fiber fragments originating from the dermis. Its use is recommended to treat superficial facial wrinkles. It is commonly used for fine, superficial wrinkles in the periorbital and perioral areas. In contrast, the collagen in Zyplast (McGhan) is cross-linked to glutaraldehyde. Although it contains the same concentration of collagen in the suspension as does Zyderm I, it provides more rigidity and should be injected deeper in the dermis. Because

of its viscosity and rigidity, Zyplast is a better choice for nasolabial and melolabial folds and for lip augmentation and deep scars. Zyplast is not indicated in the glabellar area, where the potential of vascular complications is higher with thicker materials.

Cymetra (Micronized AlloDerm: Acellular Allograft Dermal Matrix)

AlloDerm has been well accepted and is used by many specialties as a graft, spacer, and filler since its introduction in 1992. Currently, this acellular dermal graft is also available as an injectable soft tissue filler (micronized AlloDerm, or Cymetra). The skin allograft is harvested from cadaveric banked tissue and is meticulously processed to remove the antigenic components.

There are several advantages when using an acellular, immunologically inert tissue such as Cymetra. First, there should be a more enduring effect because there is no cell-mediated rejection of the tissue. Second, in theory, an acellular matrix should be a safer material as it eliminates the opportunity for viral transmission. Third, in contrast to bovine collagen, no testing is necessary prior to treatment. Finally, the acellular collagen and elastin matrix should provide a scaffold for neovascularization, host fibroblast infiltration, and proliferation with collagen deposition. In other words, the host dermis adopts the tissue and begins a repopulation process with minimal reaction, preventing rapid absorption of the material.

The best results are obtained when Cymetra is injected for correction of prominent nasolabial folds, lip atrophy, depressed scars from injury or acne, or facial creases including marionette lines. Use of Cymetra in the glabellar or periocular area should be avoided because there is increased potential for occlusion of the retinal circulation, resulting in blindness through retrograde flow. Other contraindications include known autoimmune collagen disease and sensitivity to gentamicin, cefoxitin, lincomycin, polymyxin B, and vancomycin. Poorly vascularized or infected skin areas should be avoided. Although a history of herpetic lesions in the area is not a contraindication, pretreatment with systemic antiviral medication is advised as a prophylactic measure.

With the exception of being nonallergenic, the adverse effects found with Cymetra and bovine collagen are similar. They include edema, bruising, inflammation, skin discoloration, and activation of herpetic lesions. Although the graft is processed, and donors are

screened carefully, the manufacturers of Cymetra warn that there is still a potential for infection and an allergic response.

HYALURONIC ACID

Along with Cymetra and bovine collagen, using stabilized hyaluronic acid is another option for filling areas of facial and lip atrophy. This elastic molecule is naturally found in various parts of the human body, including between collagen fibers in the skin. Being highly hydrophilic, it pulls water to itself, preventing damage by compression. With age, there is a marked reduction in the production of hyaluronic acid and in its ability to draw water.

Hyaluronic acid has been used successfully for many medical reasons including orthopedic problems and ophthalmic surgery. Replacement therapy for soft tissue augmentation has a long history worldwide but is still pending approval in the United States. Hyaluronic acid is a polysaccharide found with identical chemical composition in all living organisms, making it an attractive nonanimal, noncadaveric biomaterial. Products such as Perlane, Restylane, and Restylane Fine Lines (Q-Med, Uppsala, Sweden) are derived from bacterial fermentation and are stabilized to retard the degradation process in the dermis.

Each of these products has a different particle size, so each can address a specific problem and a specific skin layer. Restylane Fine Lines contains the smallest gel particle size and should be used in superficial wrinkles in the perioral area. The manufacturers believe it is also safe to inject Restylane Fine Lines in the periorbital area. Restylane is best used when injected into the mid-dermal or submucosal plane for facial rhytides and the vermilion border. Finally, of these three products, Perlane contains the largest gel size particle, and its placement should be in the deeper dermal plane for correction of deeper folds (e.g., nasolabial and melolabial folds) and for lip augmentation.

Stabilized hyaluronic acid has a few advantages over other biomaterials. First, the fact that it is a nonanimal product makes it an appealing, noninfectious material. Second, as the hyaluronic acid is broken down it draws more water, maintaining the volume and a longer lasting aesthetic effect throughout the degradation process.

Local side effects include edema, erythema, pain, itching, discoloration, and lumpiness at the injection site. It should be noted that

1 in 2000 patients report swelling and induration during the first 4 weeks after injection. This is considered to be a hypersensitivity reaction and should be treated with oral steroids.

TECHNIQUES FOR SOFT TISSUE ENHANCEMENT

Included in this section is a discussion of the techniques used for enhancement of nasolabial and melolabial folds, buccal atrophy, and acne scars using nonbovine tissue such as micronized acellular dermal matrix and stabilized hyaluronic acid.

Several anesthetic choices are available, with the decision depending on the treatment site, the pain threshold of the patient, and the level of comfort of the physician. Some advocate the use of ice and topical anesthetics alone to keep the facial topography undisturbed prior to injections. Others prefer to use small amounts of local anesthetic in the area of needle entrance with 1% lidocaine and epinephrine, nerve blocks, or a combination of the two. Antiseptic solution or alcohol is used to clean the area of interest.

Either one or a combination of the following techniques can be used to enhance the various facial features. The most common are subcision, linear, serial puncture, and fan techniques.

We favor the subcision technique for nasolabial and prominent melolabial folds where the level of injection needs to be deeper into the deep dermal or superficial subdermal plane. Using a long 23-gauge needle with the bevel up, the surgeon punctures the skin and advances it from the caudal limit of the nasolabial fold to its most proximal end next to the ala of the nose where the fold widens into a triangular shape. The needle is then turned bevel down and is used as a knife in a sweeping motion to create a deep dermal–subdermal space. The needle is once again turned bevel up, and the material is injected in a retrograde fashion as the controlled lift of the skin is ensured. This approach enables the surgeon to undermine and release the fold from its subdermal attachments so the material can lift up the tissue in a controlled, manageable fashion.

Although the linear technique (Fig. 11-2) can be utilized in any area, we use it more commonly for linear scars, for marionette lines, and to enhance the lips. A 23-gauge needle is used in the melolabial folds to fill in the dermal–subdermal plane in a retrograde fashion. To treat the upper and lower lips, lateral insertion into the submucosal plane of the vermilion border is performed and advanced to the midline. A

FIGURE 11-2. Linear threading technique.



23- to 26-gauge needle can be used depending on the physician's preference. The injection follows as the needle is withdrawn with the bevel up while the surgeon controls the amount of material injected. The opposite side is then injected in the same fashion. Finally, an injection parallel and posterior to the one in the vermilion border is performed slightly deeper in the body of the lips to obtain a plump look.

Serial punctures (Fig. 11-3) can be made along the area of interest. Philtrum columns, nasolabial folds, marionette lines, and scars can all be enhanced using this approach. Multiple injections should be made close to each other to prevent skip areas that would make the area feel uneven. As expected, more bleeding can occur with this technique. Finally, the fan technique is more commonly used for large areas such as during cheek augmentation. In this fashion a wider area can be easily treated with a minimal number of punctures.

In general, stabilized hyaluronic acid injections are made until the desired appearance is obtained. With Cymetra injections, over-correction of at least 50% is desirable owing to the large amount of lidocaine in the syringe after reconstituting the material. Massaging the treated area is commonly performed by the surgeon—never by the patient—to confirm uniform distribution of the filler and the lack of skip areas, which can produce an uneven appearance.

POSTOPERATIVE TREATMENT

The injection areas are expected to become edematous within minutes to hours after the procedure and usually resolve within 1–3 days. Generally, lips tend to swell more and longer than nasolabial folds

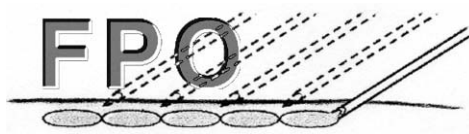


FIGURE 11-3. Serial puncture technique.

or marionette lines. The patient is instructed to keep the head of the bed elevated at bedtime, ice the treated area as much as possible, and avoid massaging the area to minimize the edema. In addition, ibuprofen 200–400 mg four times a day may be prescribed for 4 days as an antiinflammatory and analgesic. If needed, reinjections to augment an area further can be performed after 3–4 weeks.

INDEX

A

- Acellular collagen, for soft tissue augmentation, 96
- Acellular dermal matrix
 - allograft, 98–99
 - for grafts, spacers, or fillers, 95–96
- Acetylcholine, inhibition of release of, by botulinum toxin type A, 85
- Acne scars, dermal fillers for, 96
- Acyclovir (Zovirax), for treating facial herpes before skin resurfacing, 81
- Age
 - effects of
 - on the contour of the maxilla, 13–14
 - on eyelid fat, 9–10
 - on the levator muscle and the aponeurosis, 8
 - on the upper face, 26
 - gravitational syndrome and, 38
 - remodeling of the facial bones and, 14
 - superficial musculoaponeurotic system changes with, 16
- Allergy to bovine collagen, testing for, 96–97
- AlloDerm (cadaveric dermis, immunologically inert), for lip augmentation, 93
- Anatomy
 - facial, 1–23
 - of the temporal area, 31
- Anesthesia
 - local
 - in lower blepharoplasty, 72–75
 - in upper blepharoplasty, 66
 - for mid-face lift, 57

- for rhytidectomy, 46
- safety considerations in laser surgery, 82

Annulus of Zinn, 8

Antibiotics

- postoperative, in direct eyebrow lift, 42
- preoperative, in skin resurfacing, 81
- See also* Medications

Aponeurosis, topography of, relative to Whitnall's ligament, 7

- Arcus marginalis, topography of, 5
- Arteries, ethmoidal, anastomoses to, retrograde flow to after high-pressure injections, 17–18

Axithromycin (Zithromax), treatment with, before skin resurfacing, 82

B

Bell's phenomenon, measuring before upper blepharoplasty, 63

Bleeding, pinpoint, after erbium resurfacing, 84

Blepharoplasty

lower, 71–77

upper, 63–70

Blepharospasm, treatment of, with Botox, 85

Blindness, from accidental embolization of the ophthalmic artery, 18

Bony nasal turbinates, 13

Botox, facial cosmetic, 85–90

Botulinum toxin

for eyebrow elevation, 27

type A, sterile neurotoxin complex from *Clostridium botulinum*, 85

Bovine collagen, for soft tissue augmentation, 95
Brow, changes in, as a goal of endoscopic foreheadplasty, 27
Bupivacaine, for rhytidectomy anesthesia, 46

C

Cable lift, 56–57, 61
Canthal ligaments, 6
Capsulopalpebral fascia, 9
Carotid arteries, facial vasculature arising from, 17–18
Cefadroxil (Duricef), treatment with, before skin resurfacing, 82
Cephalexin (Keflex), treatment with, before skin resurfacing, 82
Cervical dystonia, Botox for treating, 85
Cheek augmentation, 96
Chin, clinical evaluation before rhytidectomy, 43–44
Ciprofloxacin (Cipro), treatment with, before skin resurfacing, 82
Clamp-cut-cautery technique, for excising fat in lower blepharoplasty, 72–74
Clostridium botulinum, source of botulinum toxin type A, 85
Collagen, for soft tissue augmentation, 96–99
Collagen tightening, dermal, effects of carbon dioxide and erbium lasers on, 80–81
Complications of Botox treatment, 90
Connective tissue
 of the eye, 5–7
 of the mid-face and lower face, 14–16
Connell's sign, 26–27
Contraindications
 to acellular allograft dermal matrix use, 98–99
 to Botox use, 87
 to forehead soft tissue augmentation, 96–97
 to skin resurfacing, isotretinoin use as, 80
Corrugator muscle, effect of, on eyebrow contour, 2, 26
Cortical bone tunnel, for fixation in endoscopic foreheadplasty, 34

Cranial nerves, innervation of the eyelids by, 11–13
Crow's feet
 Botox for reduction of, 85
 Botox injection sites, 88–89
Cymetra (acellular allograft dermal matrix), 98–99

D

Depressor supercilii muscle, effect on eyebrow contour, 2, 26
Dermatochalasis, upper blepharoplasty for managing, 63–70
Dilution of Botox, procedure for, 86–87
Dissection
 deep, superficial musculoaponeurotic system, 51–54
 subperiosteal and supraperiosteal, in endoscopic foreheadplasty, 32–33
Distichiasis, treatment of, 6
Dog ear deformity, avoiding, in superficial musculoaponeurotic system deep dissection, 52–53
Duration, of Botox treatment, 88

E

Ectropion, from laxity of the canthal ligaments, 6
Endoscope, insertion of, in foreheadplasty, 32–33
Endoscopic foreheadplasty, 25–35
Endotracheal tube, protection of, in laser skin resurfacing, 82
Epiphora, due to weakening of the eyelids, 8
Erythema, persistence of, after laser skin resurfacing, 84
Ethmoidal arteries, anastomoses to, retrograde flow to after high-pressure injections, 17–18
Etiology
 of eyebrow placement, 25–26
 of eyebrow ptosis, 38
 of lip augmentation requests, 91–92
Evaluation
 clinical
 for Botox treatment, 86
 for endoscopic foreheadplasty, 26–27
 for lip augmentation, 92
 for rhytidectomy, 43–45

- preoperative
 - for eyebrow lift, 38–39
 - for laser resurfacing, 80–81
 - for lower blepharoplasty, 71–72
 - for upper blepharoplasty, 63–64
 - Excision in the superficial
 - musculoaponeurotic system, 50
 - Eyebrow, anatomy of, 1–3
 - Eyebrow lift, direct, 37–42
 - Eyelid crease, upper, as a surgical
 - landmark, 4
 - Eyelids, 3–13
- F**
- Facial anatomy, 1–23
 - Facial expression, role of eyebrows in, 1
 - Facial irradiation, use of, as a
 - contraindication to skin resurfacing, 80
 - Facial nerve
 - innervation of the eyelids by, 11–13
 - paralysis of
 - and dissection in eyebrow lift, 40
 - eyebrow ptosis from, 38
 - protecting, in mid-face lift, 59
 - Facial vein, drainage from the eyelids
 - via, 10–11
 - Famciclovir (Famvir) for treating facial
 - herpes
 - after lip augmentation, 94
 - before skin resurfacing, 82
 - Fat pads
 - buccal, topography of, 17
 - eyelid, 9–10
 - evaluating before blepharoplasty, 64
 - lower, herniated, 71–72
 - malar
 - involutional descent of with age, 16
 - topography of, 17
 - mid-face, 17
 - removing in blepharoplasty, 66–67, 72
 - Yasergil's, plane of dissection on the
 - surface of, 58
 - Federal Drug Administration (FDA),
 - approval of Botox, 85
 - Filler materials, for lip augmentation, 92
 - Fire, in laser use, safety consideration, 82
 - Fixation, in endoscopic foreheadplasty,
 - 33–35
 - Flower's sign, 26–27
- Forehead
 - anatomy of, 1–3
 - soft tissue augmentation in,
 - contraindication to, 96–97
 - wrinkles of, treatment with Botox, 88–90
 - Forehead lift, endoscopic
 - simultaneously with mid-face lift, 61
 - simultaneously with skin resurfacing,
 - 81
 - Foreheadplasty, endoscopic, 25–35
 - Frame height, preoperative measurement
 - of, 27
 - Frontalis muscle
 - blepharoptosis masked by recruitment
 - of, 1
 - effect of, on eyebrow contour, 2
 - innervation of, by the facial nerve, 12
 - origin and function of, 25–26
 - weakening of, by Botox, 86
- G**
- Gender
 - and Botox dosage, 88
 - and eyebrow contour, 2, 25, 38
 - and margin-crease distance, 64
 - Glabellar lines
 - Botox for reduction of, 85, 90
 - effect of Botox on, 87
 - periosteal incisions to eliminate, 32
 - soft tissue augmentation in,
 - contraindication to, 96–97
 - Glide test, for measuring brow excursion,
 - 27
- H**
- Hematoma, due to anticoagulant
 - medications, 44
 - Hemostasis
 - in blepharoplasty, effect of instrument
 - choice on, 72–75
 - in rhytidectomy, 48–49
 - Herpes infection, treating
 - before lip augmentation, 94
 - before skin resurfacing, 81–82
 - before soft tissue augmentation, 98
 - Horizontal forehead lines, Botox for
 - reduction of, 85
 - Horner's muscle, 7–8
 - Horner's syndrome, involvement of
 - Müller's muscle in, 8

Human immunodeficiency virus (HIV)
infection, soft tissue atrophy in,
correcting, 96
Hyaluronic acid, stabilized for soft tissue
augmentation, 96, 99
Hyperpigmentation, postoperative, in
skin resurfacing, 81, 84
Hypersensitivity, of skin after
resurfacing, 84

I

Imbrication, superficial
musculoaponeurotic system, in
rhytidectomy, 50–51
Immunogenic properties, of Botox, 88–90
Incisions
for direct eyebrow lift, 40–41
for endoscopic foreheadplasty, 28–30
facial, for rhytidectomy, 48
for lip augmentation, 93–94
for mid-face lift
temporal, 58
vertical repositioning, 55–57
for rhytidectomy, 46–50
Innervation
of the eyelids, 11–13
facial, 18–19
of the mid-face and lower face muscles,
16
Isotretinoin use, as a contraindication to
skin resurfacing, 80

J

Jackson-Pratt drain, in rhytidectomy
management, 54
Jowls, repositioning, 50

L

Lacrimal gland
distinguishing from the eyelid fat pads,
9–10
evaluating the appearance of, before
upper blepharoplasty, 64
repositioning, in upper blepharoplasty,
68–69
Lacrimal nerve, topography of, 11–12
Lacrimal pump, 7, 8
Lagophthalmos, measuring before
blepharoplasty, 63

Laser

carbon dioxide
in lower blepharoplasty, 71
in skin resurfacing, 79–84
erbium, in skin resurfacing, 79–84
Levator aponeurosis, upper eyelid crease
formation by, 4
Levator muscle, motor innervation to, 12
Levator palpebrae superioris, 8
Lid crease, re-forming in upper
blepharoplasty, 68
Lidocaine
for endoscopic foreheadplasty, 27–28
for lip augmentation, 93–94
for mid-face lift, 57
for rhytidectomy anesthesia, 47
Linear threading, for linear scars,
marionette lines and lip
enhancement, 100–101
Lip augmentation/enhancement, 91–94
linear technique in soft tissue
augmentation, 100–101
soft tissue augmentation example,
96–97
Lipectomy
marking an incision for, 47
through a submental incision, 44
Liposuction, submental, to remove
minimal fat, 43–45
Lower face, anatomy of, 13–19
Lymphatic drainage of the eyelids, 11

M

Mandible, anatomy of, 14
Mandibular nerve, risk of surgical injury
to, 18
Margin, eyelid, 4–5
Marginal arcades, superior and inferior,
10–11
Marionette lines
linear threading for inserting
hyaluronic acid, 100–101
soft tissue augmentation for, 96–97
Marking
for direct eyebrow lift, 38–39
for endoscopic foreheadplasty, 28
for laser skin resurfacing, periorbital,
82–83
for lower eyelid skin excision, 76–77

- for perioral laser resurfacing, 82–83
- for rhytidectomy, 46–47
- for upper blepharoplasty, 64–66
- Masseter muscle, aponeurosis of, in mid-face lift, 60
- Mastication, muscles of, 16–17
- Maxilla, topography of, 13–14
- Maxillary nerve, 12
 - risk to, in dissection, 19
- Medical management
 - in endoscopic foreheadplasty, 27
 - in lip augmentation, 92
- Medications
 - effect of anticoagulants in
 - rhytidectomy, 44
 - hydrocortisone, to reduce erythema
 - after laser skin resurfacing, 84
 - narcotic analgesic, following full-face
 - laser skin resurfacing, 84
 - for treating facial herpes after lip
 - augmentation, 94
 - for treating facial herpes before skin
 - resurfacing, 81–82
- Meibomian glands, 4, 6
- Mid-face
 - anatomy of, 13–19
 - the lower eyelid as an extension of, 72
- Mid-face lift, 55–62
- Migraine headaches, Botox for treating, 85
- Mitek anchor screw, for fixation in
 - endoscopic foreheadplasty, 34–35
- Motor innervation, of the mid-face and
 - lower face, 18
- Müller's muscle, topography of, 8
- Muscle of Riolan, 7–8
 - as a surgical landmark, 4
- Musculature
 - eyebrow, effect on contour, 2
 - eyelid, 7–9
 - mid-face and lower face, 16–17
- Myobloc (botulinum toxin type B), 85–86

N

- Nasojugal fold, repositioning, 50
- Nasojugal grooves
 - assessing, before lower blepharoplasty, 72
 - improving the appearance of, 74–75

- Nasolabial fold, tightening, 50
- Neck
 - clinical evaluation before rhytidectomy, 43–44
 - elevating, suture for, 50
- Nerve blocks. *See* Lidocaine
- Neurotomy, interfascicular, in endoscopic
 - foreheadplasty, 32–33
- Nonsteroidal antiinflammatory drugs, for
 - lip augmentation patients, 94

O

- Oculomotor nerve
 - eyelid innervation by, 11–13
 - levator muscle innervation by, 12
- Ophthalmic nerve, risk to, in browlift
 - procedures, 18–19
- Orbicularis muscle
 - effect of, on eyebrow contour, 2
 - innervation of, by the facial nerve, 12
- Orbicularis oculi muscle, 7
 - origin and function of, 26
- Orbital septum, anchor to the orbicularis
 - muscle, 5–6
- Orbital wall, lateral, components of, 13–14
- Osteology, of the mid-face and lower face, 13–14

P

- Palatine bone, anatomy of, 14
- Palpebral fissure, shortening in canthal
 - ligament laxity, 6
- Perioral resurfacing, laser, 83
- Periorbital resurfacing, laser, 82–83
- Periosteum, release of, in mid-face lift, 60–61
- Peripheral arcades, superior and inferior, 10–11
- Perlane (hyaluronic acid preparation), 99
- Photodamage to the skin of the mid-face
 - and lower face, 14
- Platysmal bands, marking before
 - rhytidectomy, 46
- Plication
 - platysmal, 44–45
 - during rhytidectomy, 48
 - superficial musculoaponeurotic system, 50

- Postoperative care
 - in direct eyebrow lift, 42
 - in endoscopic foreheadplasty, 35
 - in laser skin resurfacing, 84
 - in rhytidectomy, 54
 - in soft tissue augmentation, 101–102
 - in upper blepharoplasty, 70
- Preaponeurotic fat, 5–6
- Procerus muscle
 - effect of, on eyebrow contour, 2
 - origin and function of, 26
- Ptosis
 - brow, factors contributing to, 25
 - forehead, 26
 - involutional, from dehiscence of the levator aponeurosis, 7
 - mid-face, from age-related changes of the superficial musculoaponeurotic system, 16
 - risk of, in Botox treatment, 90
- R**
- Race
 - and conformation of the eyelid crease, 4
 - and margin-crease distance, 64
- Remodeling of the facial bones with aging, 14
- Repositioning, vertical, for mid-face lift, 55–57
- Restylane Fine Lines (hyaluronic acid preparation), 99
- Retroauricular incision, in rhytidectomy, 48–49
- Retrobulbar hemorrhage, as a complication of lower eyelid skin excision, 76–77
- Retroorbicularis oculi fat (ROOF), 50
 - relationship with the eyebrow, 2
- Rhytidectomy, 14, 43–54
- Rhytids
 - facial, static and dynamic, 86
 - transverse forehead, dosages for treating with Botox, 88–90
- S**
- Safety, laser goggles for personnel in laser skin resurfacing, 82
- Sensory innervation, to the face via the trigeminal nerve, 18
- Side effects, of hyaluronic acid products for soft tissue augmentation, 99
- Skin
 - excision of, lower eyelid, 76–77
 - eyelid, 4–5
 - laser resurfacing of, 79–84
 - mid-face and lower face, 14
- Smoke evacuator, for use in laser skin resurfacing, 82
- Smoking, flap necrosis secondary to vasoconstriction due to, 44
- Soft tissue
 - attachments supporting the superficial musculoaponeurotic system, 15–16
 - augmentation of, 95–102
- Sphenoid, as a lateral orbital wall component, 13–14
- Staples, cardinal, in superficial musculoaponeurotic system imbrication, 52
- Steatoblepharon, in aging, 9–10
- Strabismus, treatment with Botox, 85
- Stroke, from accidental embolization of the ophthalmic artery, 18
- Subcutaneous tissues of the mid-face and lower face, 14
- Subincision, for nasolabial and melolabial folds, 100
- Submental fat, removal of, incision placement for, 46
- Submental liposuction, marking an incision for, 47–48
- Suborbicularis oculi fat (SOOF), 17
 - plane of, for vertical repositioning in mid-face lift, 55–57
- Subperiosteal plane, for vertical repositioning in mid-face lift, 55–57
- Superficial musculoaponeurotic system (SMAS)
 - anatomy of, 14–16
 - investment of the zygomaticus major and minor, and the levator labii superioris in, 16
 - management of, in rhytidectomy, 46–54
 - modification of, goals, 49–50
- Superficial temporoparietal fascia (SMAS), suturing through, in mid-face lift, 61
- Supraorbital nerve, innervation of the forehead by, 12

- Supraorbital notch, marking, before
direct eyebrow lift, 39
- Supratrochlear nerve, innervation of the
upper eyelid and forehead by, 12
- Surgical management/technique
in direct eyebrow lift, 39–41
in endoscopic foreheadplasty, 27–33
in lip augmentation, 93–94
in lower blepharoplasty, 72–77
in mid-face lift, 57–61
in rhytidectomy, 46–54
for upper blepharoplasty, 64–69
- T**
- Tarsal muscle, inferior, lower eyelid
retraction involving, 9
- Tarsal plates, 5–6
- Tear secretion, measuring, 63
- Techniques
for laser skin resurfacing, 82
for soft tissue enhancement, 100–101
See also Surgical
management/technique
- Teeth, protecting, in perioral laser
resurfacing, 83
- Temporal area, anatomy of, 31
- Temporal nerve, risk of surgical injury to,
18
- Temporoparietal fascia, anatomy of,
58–59
- Tenon's fascia, lower eyelid retractor
insertion on, 9
- Topography
of the eyelid, 3–4
of the superficial musculoaponeurotic
system, 15–16
- Transconjunctival blepharoplasty
lower, 72–75
simultaneously with skin resurfacing,
81
- Trigeminal nerve
mandibular branch, structures
innervated by, 19
risk of surgical injury to, 18
sensory innervation of the eyelids by,
11–13
- Turbinates, bony nasal, 13
- V**
- Valacyclovir (Valtrex), for treating facial
herpes, 82
- Vasculature
eyelid, 10–11
facial, 17–18
- Volume augmentation for mid-face lift,
55
- W**
- Whitnall's ligament, eyelid support from,
7–8
- Whitnall's tubercle, 6
- Y**
- Yasergil's fat pad, locus of a plane of
dissection, 58
- Z**
- Zyderm (bovine collagen), 97
- Zygoma, lateral facial buttress formed
from, 13–14
- Zygomatic arch, release of the periosteum
over, in mid-face lift, 59
- Zygomatic branch, of the trigeminal
nerve, 12
- Zyplast (collagen cross-linked with
glutaraldehyde), 97–98